

More than 30 years of experience
with ePTFE in medical implants



PERFORMANCE through experience



PRECLUDE®

PERICARDIAL MEMBRANE

Features and Benefits

Bioinert

Biocompatible

Minimal tissue attachment

Clear plane of dissection

Long-term flexibility

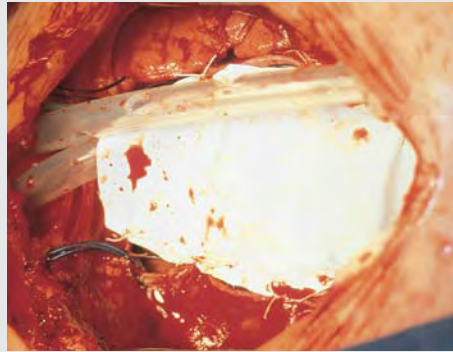


Photo courtesy of Professor Roland Hetzer, MD

GORE PRECLUDE® Pericardial Membrane as seen at time of implantation

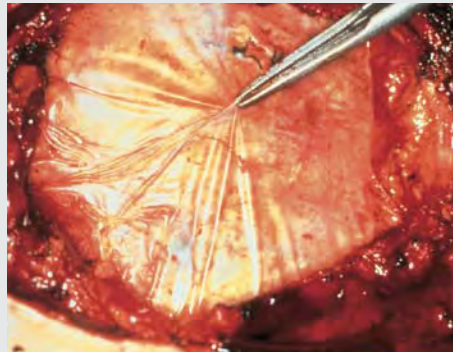


Photo courtesy of Yumi Imai, MD

GORE PRECLUDE® Pericardial Membrane as seen at seven years implantation. After implantation the material becomes wet with proteinaceous, aqueous fluids and turns translucent^{1,2,3}. Minimal adhesion formation was noted and the material was non-adherent to the epicardial surface of the heart.

IDEAL FOR USE WITH LEFT VENTRICULAR ASSIST DEVICE (LVAD) OR TOTAL ARTIFICIAL HEART (TAH)

Aids in device removal during reoperation and reduces removal time from 2 hours to ≤ 1 hour^{4,5}.

“Using ePTFE membrane to fashion a complete neo-pericardium and to wrap the ascending aorta at the time of Cardio West implantation dramatically reduces adhesions and pericardial thickening and facilitates explantation⁴.”

“Use of ePTFE membranes in patients undergoing bridge to transplantation with either an LVAD or TAH limited adhesions between tissues and device surfaces without increasing the risk of infection⁵.”

Sizing / Implant Techniques

Reoperative experience and current implantation techniques support placement of the GORE PRECLUDE® Pericardial Membrane between the epicardial surface of the heart and the pericardium^{1,2}. **It is essential that the membrane be tailored to the size of the repair site.** If the GORE PRECLUDE® Pericardial Membrane is too small, impairment of cardiac function may occur, and sutures may pull out.

If the GORE PRECLUDE® Pericardial Membrane is too large when implanted, excessive wrinkling may occur, possibly resulting in undesired tissue attachment caused by accumulation of blood next to the heart. Tucking the membrane at least 2 cm under the edge of the pericardium can prevent attachment of the pericardial incision to the epicardium. **Wrinkling can be minimized by partially closing the sternal retractors prior to completion of the implantation of the GORE PRECLUDE® Pericardial Membrane².**

USE WITH LVAD or TAH

Reconstruction of the pericardium with GORE PRECLUDE® Pericardial Membrane concurrent with implantation of mechanical circulatory assist devices should be completed utilizing the recommended techniques of handling, sizing, and suturing in the *Instructions for Use*. If multiple pieces of the GORE PRECLUDE® Pericardial Membrane are required for the repair, they should be sutured together with non-absorbable monofilament suture. Removal of mechanical circulatory assist devices has been facilitated when the GORE PRECLUDE® Pericardial Membrane is employed in this manner.

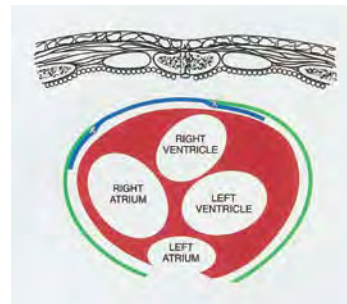
INTERNAL MAMMARY ARTERY (IMA) WRAPPING

When placing the GORE PRECLUDE® Pericardial Membrane around the IMA pedicle, it is essential that the membrane be tailored to the size of the pedicle. If the width of the membrane is inadequate, the resulting sleeve may compress the pedicle, causing graft occlusion. In addition, sutures or clips may pull out, resulting in incomplete protection. The membrane

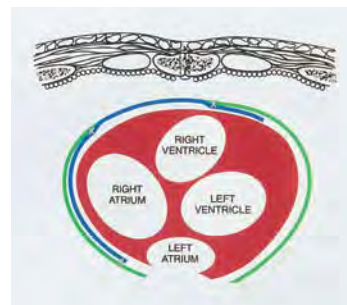
should be of sufficient length to ensure adequate coverage of the portion of the IMA pedicle at risk during re-sternotomy and dissection. Anchoring of the membrane to the pedicle or epicardium should be considered.

SUTURING TECHNIQUE

Placing sutures adjacent to the anterior cardiac surface should be minimized, to reduce epicardial fibrosis⁶. **Sutures should be placed as lateral as possible and the use of continuous suture lines should be avoided.** Non-absorbable, monofilament sutures, such as the GORE-TEX® Suture, have been used to anchor GORE PRECLUDE® Pericardial Membrane to the pericardium with interrupted stitches. Similar sutures or clips have been used to form the membrane into a sleeve around the IMA pedicle.



Protection of the anterior surface of the heart.



Protection of the anterior surface of the heart and atrial cannulation site.

USE OF DRAINS

When closure of the pericardial sac is performed, it is common practice to place two drains (in the intrapericardial and extrapericardial cavity) to remove any accumulating fluids and to be able to trace the origin of blood if bleeding occurs^{7,8}.

SIZES AVAILABLE

CATALOGUE NUMBER	WIDTH X LENGTH
1PCM001	7 cm x 10 cm
1PCM100	6 cm x 12 cm
1PCM101	8 cm x 16 cm
1PCM102	12 cm x 12 cm
1PCM103	15 cm x 20 cm
1PCM106	4 cm x 6 cm

All configurations have a membrane thickness of 0.1 mm




W. L. GORE & ASSOCIATES, INC.
Flagstaff, AZ 86004

+65.67332882 (Asia Pacific)
00800.6334.4673 (Europe)
800.437.8181 (United States)
928.779.2771 (United States)

goremedical.com

 Consult Instructions for Use

INDICATIONS FOR USE: Reconstruction or repair of the pericardium.
CONTRAINDICATIONS: Not for reconstruction of **CARDIOVASCULAR DEFECTS** such as cardiac, great vessel, and peripheral vascular, DURA MATER, HERNIAS. Use of this product in applications other than those indicated has the potential for serious complications, such as suture pullout or failure of the repair (aneurysm formation). Refer to *Instructions for Use* at goremedical.com for a complete description of all warnings, precautions and adverse events. 

Products listed may not be available in all markets.

GORE, GORE-TEX®, PRECLUDE®, and designs are trademarks of W. L. Gore & Associates.

© 2007 – 2009 W. L. Gore & Associates, Inc. AE0710-EN2 JUNE 2009

REFERENCES

1. Minale C, Nikol S, Hollweg G, Mittermayer C, Messmer BJ. Clinical experience with expanded polytetrafluoroethylene Gore-Tex surgical membrane for pericardial closure: a study of 110 cases. *Journal of Cardiac Surgery* 1988;3(3):193-201.
2. Revuelta JM, Garcia-Rinaldi R, Val F, Crego R, Duran CM. Expanded polytetrafluoroethylene surgical membrane for pericardial closure. *Journal of Thoracic & Cardiovascular Surgery* 1985;89(3):451-455.
3. Harada Y, Imai Y, Kurosawa H, Hoshino S, Nakano K. Long-term results of the clinical use of an expanded polytetrafluoroethylene surgical membrane as a pericardial substitute. *Journal of Thoracic & Cardiovascular Surgery* 1988; 96(5):811-815.
4. Copeland JG, Arabia FA, Smith RG, Covington D. Synthetic membrane neopericardium facilitates total artificial heart explantation. *Journal of Heart & Lung Transplantation* 2001;20(6):654-656.
5. Leprince P, Rahmati M, Bonnet N, Bors V, Rama A, Léger Ph., Gandjbakhch I, Pavie A. Expanded polytetrafluoroethylene membranes to wrap surfaces of circulatory support devices in patients undergoing bridge to heart transplantation. *European Journal of Cardio-thoracic Surgery* 2001;19:302-306.
6. Heydorn WH, Daniel JS, Wade CE. A new look at pericardial substitutes. *Journal of Thoracic & Cardiovascular Surgery* 1987;94(2):291-296
7. Amato JJ, Cotroneo JV, Galdieri RJ, Alboliras E, Antillon J, Vogel RL. Experience with the polytetrafluoroethylene surgical membrane for pericardial closure in operations for congenital cardiac defects. *Journal of Thoracic & Cardiovascular Surgery* 1989;97(6):929-934.
8. Cunningham JN Jr, Spencer FC, Zeff R, Williams CD, Cukingnan R, Mullin M. Influence of primary closure of the pericardium after open-heart surgery on the frequency of tamponade, postcardiotomy syndrome, and pulmonary complications. *Journal of Thoracic & Cardiovascular Surgery* 1975;70(1):119-125.

SUGGESTED READING

Bailey LL, Ze-jian L, Schultz E, Roost H, Yahiku P. A cause of right ventricular dysfunction after cardiac operations. *Journal of Thoracic & Cardiovascular Surgery* 1984;87(4):539-542.

Bezon E, Maguid YA, Gueret G, Choplain JN, Aziz AA, Barra JA. Wrapping of the left internal thoracic artery with an expanded polytetrafluoroethylene membrane. *Annals of Thoracic Surgery* 2006;8(1):383-385

Dobell AR, Jain AK. Catastrophic hemorrhage during redo sternotomy. *Annals of Thoracic Surgery* 1984;37(4):273-278.

Jacobs JP, Iyer RS, Weston JS, *et al.* Expanded PTFE membrane to prevent cardiac injury during re-sternotomy for congenital heart disease. *Annals of Thoracic Surgery* 1996;62(6):1778-1782.

Loebe M, Alexi-Meskhishvili V, Weng Y, Hausdorf G, Hetzer R. Use of polytetrafluoroethylene surgical membrane as a pericardial substitute. *Texas Heart Institute Journal* 1993;20(3):213-217.