

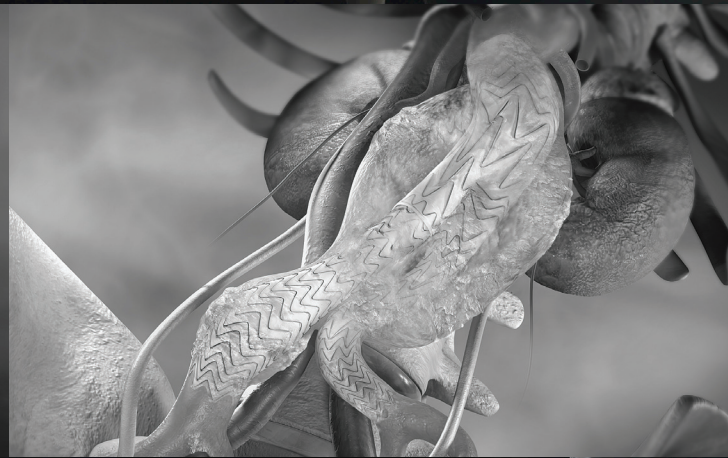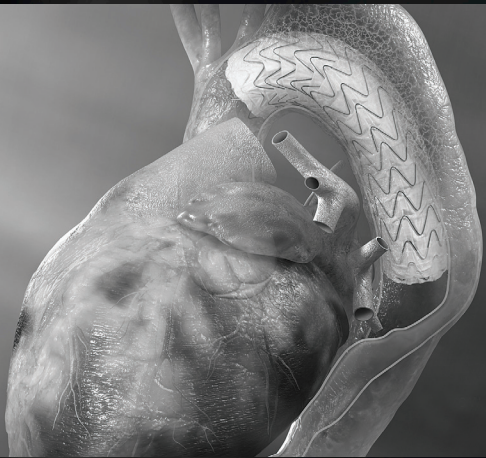# Endovascular TODAY

March 2015

# TRUSTED PERFORMANCE

DURABLE SOLUTIONS FOR THORACIC  
AND ABDOMINAL AORTIC REPAIR.

# TABLE OF CONTENTS



## **03 TECHNOLOGY AT THE CORE**

Embracing a fundamental understanding of technology to fuel product innovation.

By Josh Lovekamp, PhD

## **07 UNMET NEEDS WITH CURRENT THORACIC DEVICES**

Significant opportunities remain for research and development.

By Ali Azizzadeh, MD, FACS

## **12 INITIAL EXPERIENCE WITH THE GORE® TAG® THORACIC BRANCH ENDOPROSTHESIS**

A potential new option to address the current therapeutic limitations for Zone 2 aneurysms.

By Michael D. Dake, MD

## **16 THE USE OF TEVAR IN ACUTE UNCOMPLICATED TYPE B AORTIC DISSECTION**

Data and perspectives on the utility of endovascular repair in this challenging pathology.

By Guido H.W. van Bogaerijen, MD, and Himanshu J. Patel, MD

## **20 A NEW ANGLE ON PRECISE ENDOGRAFT PLACEMENT**

The potential benefits of orthogonal device placement in angulated aortic necks.

By Constantino S. Peña, MD, and Barry T. Katzen, MD

## **23 TAKING ADVANTAGE OF OPPORTUNITIES TO MAXIMIZE INFRARENAL SEAL**

Advantages and applicability of the GORE® C3® Delivery System.

By Robert Rhee, MD

## **27 MANAGEMENT OF AORTOILIAC ANEURYSMS: PRESERVE OR SACRIFICE THE HYPOGRASTRIC ARTERY?**

Clinical experience with the GORE® EXCLUDER® Iliac Branch Endoprosthesis.

By Reza Ghotbi, MD, and Sylvia Schoenhofer, MD



# Technology at the Core

Embracing a fundamental understanding of technology to fuel product innovation.

BY JOSH LOVEKAMP, PhD

Gore & Associates was founded by Bill and Vieve Gore in 1958 as a technology company focused on exploiting the unique properties of polytetrafluoroethylene (PTFE), a polymer that Bill had worked with as a chemical engineer and scientist at DuPont. Since the development of our first product, the MULTI-TET® Flat-Ribbon Cable for electronics applications, we have leveraged our ability to manipulate PTFE to develop thousands of products in numerous markets. In large part, this was made possible by Bob Gore, one of Bill and Vieve's five children, who is credited with many of the innovations responsible for the success of our company, including the process used to create expanded PTFE (ePTFE) (Figure 1). This basic process is still in use today to create ePTFE films, sheets, tapes, tubes, and fibers for use in applications ranging from consumer fabrics and energy-efficient fuel cells to vascular and endovascular grafts. In each case, we utilize our advanced ePTFE core technology in combination with a variety of enabling technologies and a fundamental understanding of each application in order to create and deliver reliable, high-value products that perform as promised to enhance quality of life.

Today, Gore & Associates is composed of four divisions that are defined primarily by the markets that they serve (Electronic Products, Industrial Products, Fabrics, and Medical Products). These product divisions are connected by a common reliance on our core technology expertise to lay the foundation for future new products and product innovation (Figure 2). This corporate architecture underscores the fact that we are a global enterprise dedicated to applying our unique materials, capabilities, and technical expertise to solving complex challenges. The success of this approach relies on our ability to continue to identify both the opportunities for technology advancement and the possible synergies that exist across relatively diverse product markets.

Some examples of relatively dissimilar product markets that benefit from the synergistic development of underlying core technologies include filtration membranes and gaskets for industrial applications, semipermeable barriers for sensitive electronics, and fabric garments to protect military and police personnel against environmental, chemical, and biologic threats. Each of these leverage the common know-how developed over decades of experience with the various forms of our core technology. In



Figure 1. Bill and Vieve Gore, founders of Gore & Associates (left), and their son, Bob Gore, recreating his 1969 discovery of the process for creating ePTFE (right).

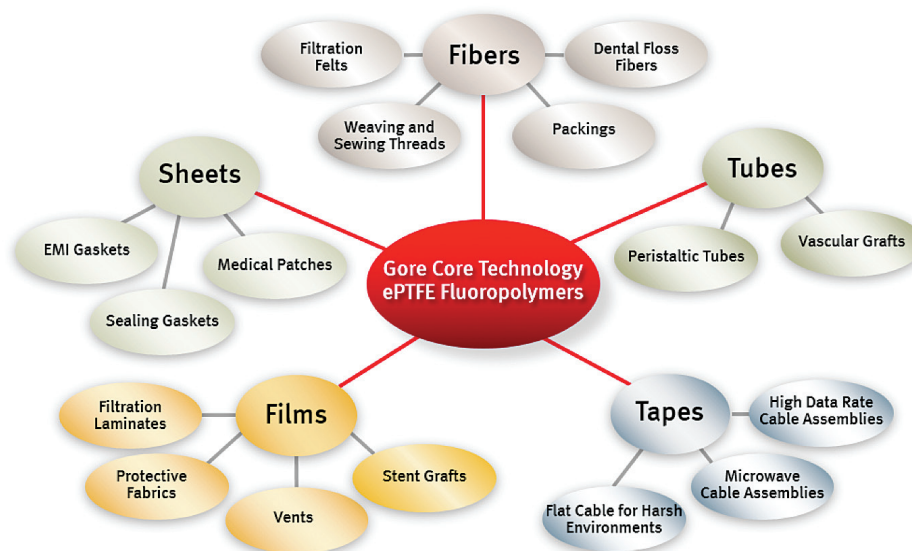


Figure 2. The commitment to our core and complementary technologies has resulted in a broad array of forms and modifications to support products in diverse applications across the four product divisions.

addition, Gore has the unique ability to design each and every layer of ePTFE that goes into our products, beginning with the properties of a specific PTFE resin, through processing, and finally with the construction of a finished product. This depth of influence and expertise throughout the value stream enables the creation of sophisticated products with material properties that are engineered to uniquely suit the needs of the applications for which they are intended.

### LEVERAGING TECHNOLOGY FOR MEDICAL PRODUCTS

Like the original MULTI-TET Wire Product, the development of the GORE-TEX® Vascular Graft was the result of Bill Gore's search for applications that might uniquely benefit from the properties of ePTFE. In this case, the inert nature of PTFE and the ability to tailor the biologic response by manipulating the microstructure through expansion contributed to making this an ideal application (Figure 3). However, early clinical experience emphasized the importance of our cross-discipline technology development. Physiologic pressurization of vascular grafts in some cases had led to creep, or gradual dilation, of the ePTFE tubes. Previous development of our high-strength ePTFE films for nonmedical applications allowed for the ability to rapidly address the problem by introducing a new version of the product that incorporated a reinforcing layer to ensure creep resistance.

Today, the evolution of vascular surgery has provided less-invasive endovascular options for patient care. From the perspective of implant manufacturers, this has come at the cost of additional device complexity and

technological demands. We have chosen to address this demand in much the same way that we have our ePTFE technology. That is, through the formation of a deep understanding of these complementary technologies. In this way, we not only enable our existing generation of products, but ultimately we can leverage this knowledge base in order to create additional unique, high-value products in the future. This approach is exemplified by the investments we have made in strategic technologies such as nitinol metallurgy, catheter-based delivery systems, and bioactive functionalization of ePTFE such as with the CBAS® Heparin Surface. These and other investments in technology and, consequently, our capabilities allow us to continue to innovate in areas where we have developed distinctive capabilities.

### DISTINCTIVE CAPABILITIES FOR THE AORTIC ENDOVASCULAR MARKET

Within our aortic endovascular business, we have identified multiple vectors for product development where our technology expertise creates the opportunity to provide unique value. Specifically, these development vectors are low profile, conformability, controlled deployment, and branched technology (Table 1). While these vectors are by no means unique in that the demand has been created by the marketplace, our ability to execute upon them is believed to be unique as a result of the investments we have made in the underlying technologies required.

Our distinctive capabilities are brought about in two ways. First, having deep knowledge regarding the technology embedded in our devices provides a better



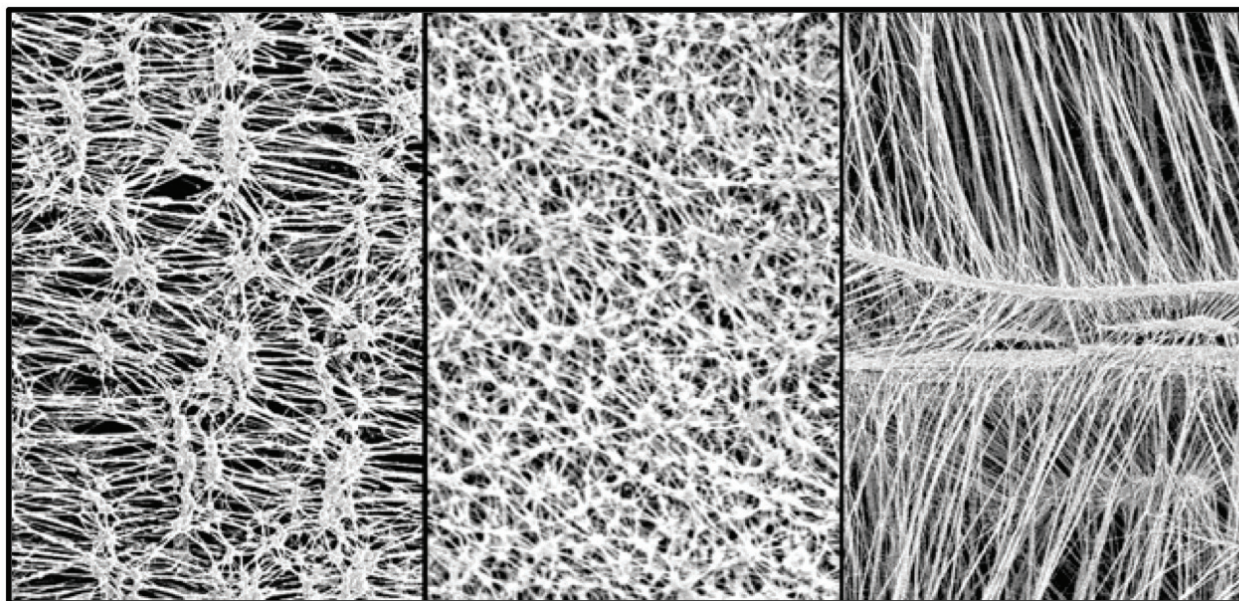


Figure 3. Various microstructures of ePTFE membranes.

framework to drive future innovation. Second, this deep knowledge also affords us the opportunity to influence the design of products with many more knobs to turn. In other words, because we design, create, and understand our products, including the critical components and subcomponents, we have the freedom to tailor the properties of each in ways that allow us to tune the performance of the final product to achieve the desired result (eg, PTFE resin properties, ePTFE film tensile strength, ePTFE film porosity, nitinol wire processing conditions).

The Conformable GORE® TAG® Thoracic Endoprosthesis is a good example of the value we are

able to derive from our distinctive capabilities. The primary motivation for this effort was to design a thoracic endograft that was safe and effective in the treatment of patients with traumatic aortic transections. In the delivery of the final product, we leveraged our deep knowledge in nitinol technology to provide a stent frame with expanded oversizing windows and improved fatigue and compression resistance. The design also incorporated changes to the ePTFE graft construction and the mechanism of graft attachment that provided a more flexible, conformable design. As a result, we were successful in bringing a device to

**TABLE 1. AORTIC DEVELOPMENT VECTORS LEVERAGE DISTINCTIVE CAPABILITIES THAT ARE MADE POSSIBLE BY OUR CORE AND STRATEGIC ENABLING TECHNOLOGIES**

#### LOW PROFILE

Utilizing advanced fluoropolymers, coupled with our deep expertise in nitinol technology, enables us to engineer materials that have the potential to reduce profile while maintaining device durability.

#### CONFORMABILITY

Building on more than 55 years of ePTFE experience enables us to optimize fluoropolymer forms and structures, stent geometry and a proprietary stent-to-graft bonding process resulting in durable and dependable solutions to maintain wall apposition and seal in complex anatomies.

#### CONTROLLED DEPLOYMENT

Combining innovative catheter technology with ePTFE fiber-actuated deployment, we actively engineer intuitive delivery systems designed to optimize precise placement and enhanced control throughout the deployment process.

#### BRANCHED TECHNOLOGY

Our proprietary ePTFE and CBAS® Heparin Surface technology and extensive experience designing both large- and small-diameter stent grafts enable us to engineer both aortic and branch components to create durable, off-the-shelf designs for the safe and reliable treatment of the entire aorta, including the branch vessels.

market that not only met the needs of the transection patient population (e.g., expanded oversizing windows, improved fatigue resistance, enhanced conformability), but also provided benefits over previous thoracic endograft designs in all etiologies.

### LOOKING FORWARD

New examples of how Gore is leveraging the fundamental understanding of our core and strategic-enabling technologies are currently under development or nearing market introduction. These include products that incorporate advances in each of the development vectors

identified for the aortic endovascular market, as enabled by our distinctive capabilities.

We share our customers' priorities and perspectives. Our close working relationships help us understand the problems that they face and uncover the best solutions for each in order to improve patient outcomes. We are committed to delivering meaningful advancements that set the standard of performance for today and tomorrow. ■

*Josh Lovekamp, PhD, is a Technical Leader for the Aortic Business Unit of Gore & Associates. He may be reached at [jlovekam@wlgore.com](mailto:jlovekam@wlgore.com).*

# Unmet Needs With Current Thoracic Devices

Significant opportunities remain for research and development.

BY ALI AZIZZADEH, MD, FACS

The first open thoracic aneurysm repair was reported by Cooley and DeBakey in 1952.<sup>1</sup> Open repair became the gold standard for all lesions of the thoracic aorta over the next 5 decades. A minimally invasive alternative, endovascular repair, was pioneered independently by Volodos in Russia (1986) and Parodi in Argentina (1991).<sup>2,3</sup> Using this new, disruptive technology, the first series of 13 patients undergoing thoracic endovascular aortic repair (TEVAR) using physician-made devices in the United States was reported by Dake in 1994.<sup>4</sup> The first thoracic device, however, did not gain US Food and Drug Administration (FDA) approval until 2005 (Figure 1).

The significant lag time from concept to market reflects the challenges involved in designing a device that can treat the wide-ranging pathologies of the thoracic aorta. The lesions in the thoracic aorta can range from penetrating aortic ulcer and intramural hematoma to aortic dissection, aneurysmal degeneration, and traumatic injury. As a result, the patient's age, aortic diameter, and blood flow velocities are widely variable. Moreover, in comparison to the abdominal aorta, the thoracic aorta is more compliant and subject to higher displacing forces as well as longitudinal loads arising from flow, pressure, and motion. There are also longer segments of disease that require coverage with relatively shorter landing zones. All of the above factors make the thoracic aorta a very challenging anatomical bed and, naturally, a significant area of opportunity for research, development, and innovation (Figure 2).

## EARLY EXPERIENCE

The United States physician experience with TEVAR after FDA approval barely spans a decade. As with any new, disruptive technology, the early years have been marked by rapid adoption of this therapy into the armamentarium of surgeons who treat aortic disease. The on-label indication started with aneurysms but rapidly evolved into isolated lesions and finally expanded into aortic dissection.



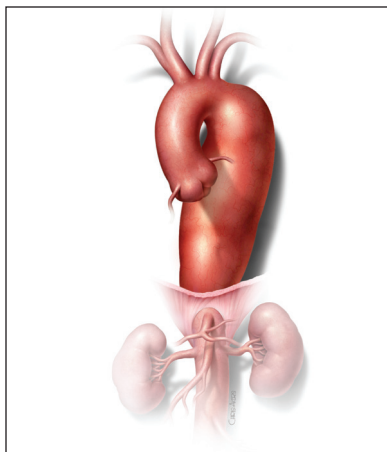
Figure 1. The GORE® TAG® Thoracic Endoprosthesis was the first thoracic device to gain US FDA approval in 2005.

Today, all lesions of the thoracic aorta can be treated on label with an FDA-approved device. In addition to expanding indications, new techniques have evolved to mitigate the challenges and complications associated with TEVAR. With the first-generation devices, physicians learned to use unique tips and tricks to maximize the applicability of this treatment modality to their patients. Naturally, with increased experience and use, a number of failure modes emerged. In a 2009 summary, Lee discussed a wide range of failure modes related to delivery, deployment, conformability, device collapse, component separation, stent fracture, and fabric tear in first-generation devices.<sup>5</sup> These findings further stressed the importance of follow-up surveillance imaging in patients who undergo TEVAR (Figure 3).

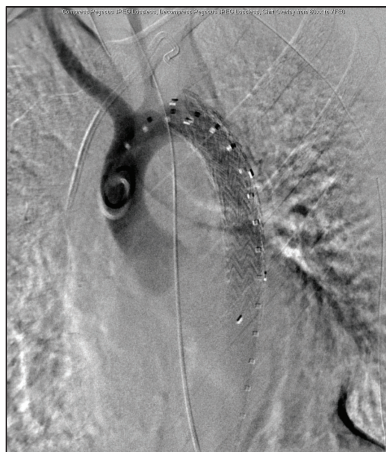
## Second-Generation Devices

As expected, second-generation thoracic devices provided a significant forward leap in meeting the challenges of the thoracic aorta. There has been an expansion in available device diameters that are able to treat a wider range of pathologies. The newer-generation devices





**Figure 2.** The descending thoracic aorta, compared to the abdominal aorta, is more compliant and subject to higher displacing forces and longitudinal loads arising from flow, pressure, and motion. The longer segments of disease and shorter landing zones make it a challenging anatomical bed.



**Figure 3.** Inadequate inner-curve apposition or bird-beaking in a young patient with traumatic aortic injury. A narrow radius of curvature is noted in the aortic arch.



**Figure 4.** The Conformable® GORE® TAG® Thoracic Endoprosthesis is a second-generation thoracic device.

are more conformable, maintain improved inner curve apposition, and perform in a wide range of anatomic and physiologic environments (Figure 4).

Many of the complications associated with the first-generation devices, such as bird-beaking and collapse, have been significantly reduced. As the technology and physician expertise have improved, the therapy is being applied to increasingly more complex and challenging clinical scenarios. As a result, significant opportunities for research and development remain. These opportunities for development can be broadly categorized into three areas: delivery, deployment, and postdeployment.

## OPPORTUNITIES FOR DEVELOPMENT

### Delivery

Delivery can be defined as the ability to place the device into its intended location. The incidence of access complications in the early days of TEVAR approached 20%.<sup>6</sup> Lower device profiles and improved operator experience have significantly reduced the incidence of access complications. There has also been a major shift from open femoral exposure toward totally percutaneous aortic interventions.

The current delivery systems include sheathless as well as integrated-sheath device platforms. There are advantages and disadvantages associated with each. A sheathless platform requires placement of a separate sheath for delivery. The advantage is that multiple devices can be deliv-

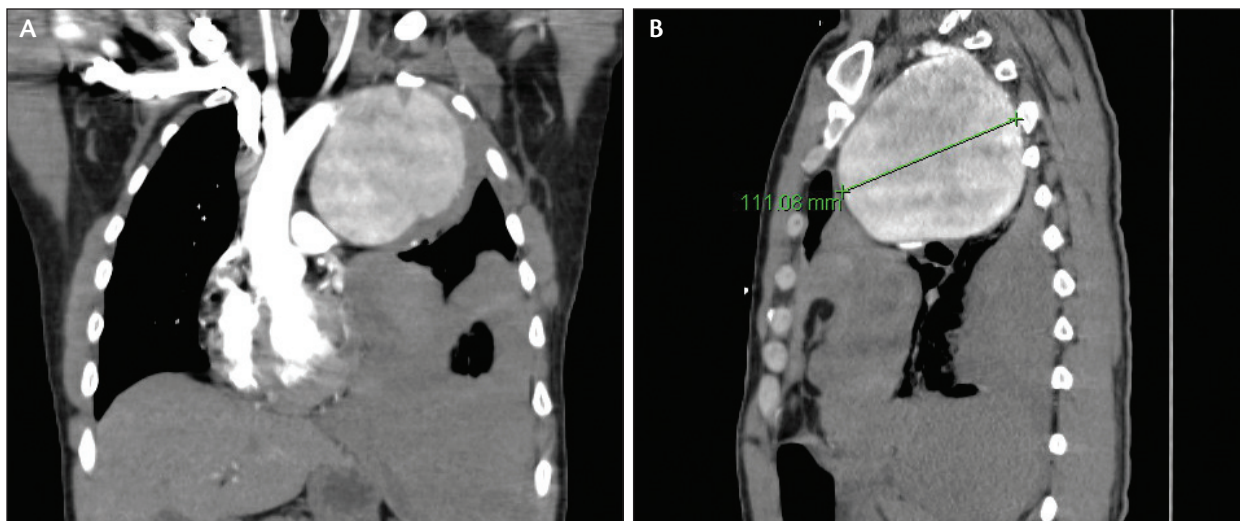
ered through a single sheath. The access vessel has to be traversed only once, with a hypothetically lower risk of trauma in difficult anatomies. It is important to note that sheaths are measured based on their inner diameter, so access site measurements have to account for that difference in diameter. Conversely, devices with an integrated sheath platform do not require a separate sheath. The access vessels have to be traversed more than once when multiple pieces are required. Measurements are based on the device delivery system outer diameter.

Regardless of the delivery system, opportunities exist to reduce device profiles. In addition, devices with improved flexibility and trackability are useful in patients with challenging anatomies.

### Deployment

The origin of the word deploy is from the French word *déployer*, which means “to unfold.” For the purpose of this article, deployment can be defined as the process of unfolding or releasing the device from its delivery profile into its final diameter. Deployment accuracy would be the ability to deploy the device at its intended location. To achieve a high degree of deployment accuracy, operator control is necessary to offset the dynamic nature of the target anatomy or landing zone.

The force of the cardiac output results in significant caudal displacement forces that can cause wind socking during deployment. There is also significant movement



**Figure 5.** Coronal (A) and sagittal (B) CTA of a 47-year-old man with a history of open aortic coarctation repair who presented with an 11-cm ruptured descending thoracic aortic aneurysm.

within the aorta, depending on the stage of the cardiac and respiratory cycles. In addition, built-up energy from tortuous and angulated anatomy can shift the device further proximal or distal than the intended location. The device frequently travels on a wire placed in the centerline of the aorta. After deployment, however, the device often hugs the outer curve. This may cause an unpredictable shift in the device position, resulting in suboptimal deployment. This effect can be very pronounced in patients who have large aneurysms and a very short proximal landing zone (Figures 5 and 6).

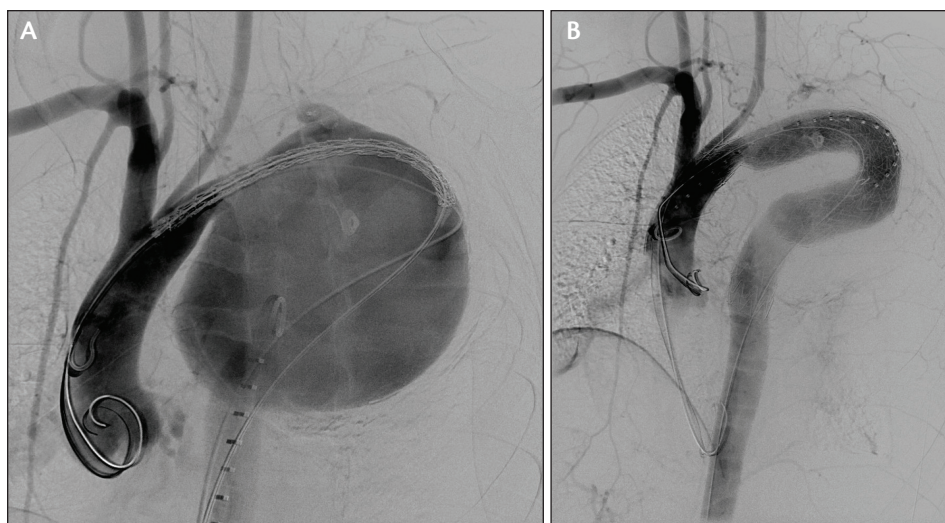
Ideally, the operator should have the ability to make fine adjustments to accommodate the dynamic nature of these factors. Naturally, a multiple-stage deployment system would be more desirable than a single-stage one. This would allow the operator to fine-tune the device deployment in the intended delivery location. One solution would be to have an intermediate-diameter profile during the first phase of deployment.

Adjustments can be made as necessary to fine-tune the device location. It would be critical to have free flow through

the device at this interval to avoid wind socking and caudal displacement. An additional angiogram can be done at this time for confirmation. The device should be placed against the outer curve of the aorta to minimize movement during the final stage of the deployment, which can be done by applying forward tension on the guidewire. With the device in its final intended position, the deployment can be completed.

#### Postdeployment Modification

Even after achieving a high degree of deployment accuracy, there are additional maneuvers that can be



**Figure 6.** Diagnostic (A) and completion (B) angiograms after TEVAR in the patient shown in Figure 5. The devices appose to the outer curvature of the aneurysm.

done to improve device apposition to the inner curvature of the aorta. This is often performed with the help of postdeployment angioplasty using a compliant balloon. Further advancements in device design can allow the operator to articulate the proximal end of the device. Such capabilities can help eliminate bird-beaking and maximize the seal zone. FDA-approved endostaples are another useful tool that can be applied to high-risk landing zones, although endostaples have not been tested with all devices.

### Branched Devices

Lesions affecting the thoracic aorta can extend to the aortic arch or abdominal aorta. In such cases, endovascular repair may require coverage of the left subclavian or celiac arteries. An off-the-shelf, branched device can expand the application of TEVAR in patients who require extended coverage. Two branched device platforms designed for the left subclavian artery are currently under investigation. The application of this off-the-shelf, branched technology to lesions of the thoracic aorta holds great promise.

### Follow-up

The significance of follow-up surveillance imaging protocols cannot be overemphasized. A number of studies have shown that delayed complications, such as endoleak or migration, can occur in late follow-up, even after an initial stable repair.<sup>7</sup> Adequate follow-up often allows physicians to intervene on complications of TEVAR before they can have catastrophic consequences. The benefits of follow-up imaging protocols have to balance against the harmful effects of cumulative radiation. Yearly CT scans over the lifetime of a young trauma patient can quickly

add up to significant radiation exposure. Alternative follow-up strategies should be investigated. Implantable pacemakers that provide diagnostic information during interrogation are in common use today. Future endograft designs could provide real-time information in a similar fashion without the need for contrast or radiation.

### CONCLUSION

Significant progress has been made during the past decade in the disruptive technology we now call TEVAR. There have been major advances in device design, physician expertise, clinical care, and research. Future progress will undoubtedly make this technology applicable to a wider spectrum of patients. ■


*Ali Azizzadeh, MD, FACS, is Professor and Chief of Vascular and Endovascular Surgery, Department of Cardiothoracic and Vascular Surgery, University of Texas Houston Medical School and Memorial Hermann Heart and Vascular Institute in Houston, Texas. Dr. Azizzadeh has disclosed that he is a consultant for Gore & Associates and Medtronic. He may be reached at [ali.azizzadeh@uth.tmc.edu](mailto:ali.azizzadeh@uth.tmc.edu).*

1. Cooley DA, DeBakey ME. Surgical considerations of intrathoracic aneurysms of the aorta and great vessels. *Ann Surg.* 1952;135:660-680.
2. Volodos NL, Shekhanin VE, Karpovich IP, et al. A self-fixing synthetic blood vessel endoprosthesis. *Vestn Khir.* 1986;137:123-125.
3. Parodi JC, Palmaz JC, Barone HD. Transfemoral intraluminal graft implantation for abdominal aortic aneurysms. *Ann Vasc Surg.* 1991;5:491-499.
4. Dake MD, Miller DC, Semba CP, et al. Transluminal placement of endovascular stent-grafts for the treatment of descending thoracic aortic aneurysms. *New Engl J Med.* 1994;331:1729-1734.
5. Lee WA. Failure modes of thoracic endografts: prevention and management. *J Vasc Surg.* 2009;49:792-799. doi: 10.1016/j.jvs.2008.12.068.
6. Bavaria JE, Appoo JJ, Makaroun MS, et al; Gore TAG Investigators. Endovascular stent grafting versus open surgical repair of descending thoracic aortic aneurysms in low-risk patients: a multicenter comparative trial. *J Thorac Cardiovasc Surg.* 2007;133:369-377. Epub 2007 Jan 8.
7. Wong S, Mastracci TM. Part one: for the motion. All TEVAR patients must be followed lifelong by annual CTA/MRA. *Eur J Vasc Endovasc Surg.* 2012;44:534-537.



# Trusted Performance


TODAY and TOMORROW



**TOMORROW**  
Thoracic Branch  
Stent-Graft\*



**TOMORROW**  
Conformable Thoracic  
Stent-Graft with  
Staged Delivery\*



**TODAY**  
Conformable GORE® TAG®  
Thoracic Endoprosthesis

## Time Tested. Future Focused.

**EXPERIENCE** delivering TEVAR solutions for more than 16 years

Proven **DURABILITY** and strength\*\*

The standard for **CONFORMABILITY** *without compromise*

Learn more at [goremedical.com/aortic/tevar](http://goremedical.com/aortic/tevar)

\* Products are under development and not available or approved for sale in any market.

\*\* Data on file.

Please see accompanying prescribing information in this journal.

W. L. Gore & Associates, Inc. • Flagstaff, AZ 86004 • [goremedical.com](http://goremedical.com)

Products listed may not be available in all markets.

GORE®, PERFORMANCE BY DESIGN, TAG®, and designs are trademarks of W. L. Gore & Associates.  
© 2014, 2015 W. L. Gore & Associates, Inc. AT1157-EN4 MARCH 2015



THORACIC  
ENDOPROSTHESIS

**PERFORMANCE**  
by design

# Initial Experience With the GORE® TAG® Thoracic Branch Endoprosthesis\*

A potential new option to address the current therapeutic limitations for Zone 2 aneurysms.

BY MICHAEL D. DAKE, MD

Historically, standard thoracic endovascular aneurysm repair (TEVAR) has been limited to anatomies with proximal necks of 15 mm to 20 mm. Unfortunately, many patients who may benefit from endovascular treatment with disease in the proximal segment of the descending thoracic aorta may not have the required proximal neck.

In order to gain the additional neck length needed for successful repair, the left subclavian artery is typically covered during TEVAR. This coverage has been associated with perioperative stroke<sup>1</sup> and spinal cord ischemia.<sup>2</sup> To aid in mitigating these problems, the Left Subclavian Artery (LSA) can be revascularized through left subclavian bypass or transposition; however, these methods require a surgical component to the procedure. The GORE® TAG® Thoracic Branch Endoprosthesis (Figure 1), which is currently undergoing a feasibility study in the United States, offers a complete endovascular solution for aneurysms that involve the proximal descending thoracic aorta.

This article discusses the current investigational experience with the GORE TAG Thoracic Branch Device and highlights its unique potential to treat this challenging anatomy.

## DEVICE OVERVIEW AND IMPLANTATION TECHNIQUE

The GORE TAG Thoracic Branch Device has an Aortic Component with an internal portal that allows insertion, seal, and fixation of the Side Branch Component, and an optional Aortic Extender for proximal extension if necessary. An additional investigational accessory used in conjunction with the GORE TAG Thoracic Branch Device is the GORE® DrySeal Side Branch Introducer Sheath.

The Aortic Component comes in device diameters of 21 mm to 53 mm, allowing an aortic treatment range of



Figure 1. The GORE TAG Thoracic Branch Endoprosthesis system.

16 mm to 48 mm. The device features sealing cuffs on both ends and a partially uncovered stent on the proximal end to aid in wall apposition.

The Side Branch Component took several years to develop to meet the many demands of the aortic arch in terms of movement, translation, and cardiac pulsation. It is covered with the CBAS® Heparin Surface, a covalently bound heparin designed for thromboresistance. The Side Branch Component was designed with three distinct segments: the branch vessel, the middle tapered, and portal segments. The branch vessel segment is deployed into the perfused side branch vessel and is designed for optimal circumferential seal. The portal segment docks within the Aortic Component

and has three anchors to prevent any slippage or migration. The middle tapered segment is flexible, allowing the Side Branch Component to accommodate arch movement.

The Aortic Component is delivered over both a side branch wire and main aortic wire. To improve the ease of aligning the device with the branch vessel, the unique delivery system features a pre-cannulated side branch wire.

There are two different portal diameters that accommodate a wide range of Side Branch Components to create numerous possible device configurations. The Side Branch Component is available in 8 mm to 20 mm diameters with a treatment range of 6 mm to 18 mm. To implant the GORE TAG Thoracic Branch Device, the guidewires are first inserted into the aorta and branch vessel. The Aortic Component is then introduced over both guidewires into position within the arch. After deployment of the Aortic Component, the GORE DrySeal Side Branch Introducer Sheath is advanced through the Aortic Component. The dilator is removed, and the Side Branch Component is advanced and deployed.

## OVERVIEW OF THE FEASIBILITY STUDY

This nonrandomized, multicenter, prospective feasibility study is being conducted at six clinical investigative sites in the United States with the objective of assessing the feasibility of the GORE TAG Thoracic Branch Device. A minimum of 20 and a maximum of 40 subjects will be enrolled into the study. Enrolled subjects will be followed after the initial treatment for five years or until termination of the trial. The primary objective of the study is to assess the feasibility of the use of the GORE TAG Thoracic Branch Device to treat aneurysms involving the proximal descending thoracic aorta that require placement of the proximal extent of the aortic stent-graft in Zone 2 (LSA) (Figure 2). Dissection and trauma patients are excluded from the current study.

The primary endpoints of the study are successful access and deployment of the GORE TAG Thoracic Branch Device and procedural side branch patency assessed by angiography at the conclusion of the endovascular procedure. The secondary endpoints include one-month side branch primary patency and one-month device-related endoleaks, both assessed by an independent core lab.

The next phase of the study will assess the GORE TAG Thoracic Branch Device for the treatment of aneurysms in the aortic arch that require placement of the proximal extent of the device in Zone 0 (Brachiocephalic) and Zone 1 (Left Common Carotid). This study was approved

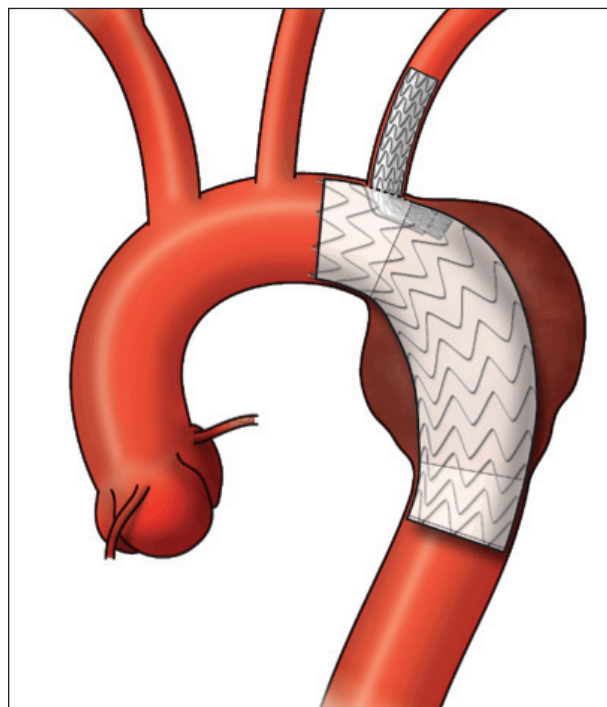


Figure 2. The GORE TAG Thoracic Branch Endoprosthesis placed in Zone 2 of the thoracic aorta.

as an Early Feasibility study in May 2014. The primary and secondary endpoints for the Zone 0/1 clinical trial are the same as Zone 2. Finally, the same six sites from the Zone 2 trial will participate in the Zone 0/1 trial, with patient follow-up continuing to five years.

## CASE STUDY

An 84-year-old man presented with a dumbbell-shaped aneurysm that was initially diagnosed by a chest radiograph (Figure 3). The proximal lobe of the aneurysm had a maximum diameter of 48 mm, and the diameter of the distal component was 68 mm. Treatment with a traditional Conformable GORE® TAG® Device would require coverage of the left subclavian artery due to the lack of proximal neck distal to the left subclavian artery. By using the GORE TAG Thoracic Branch Device, the LSA remains perfused while treating the aneurysm.

Wires were placed in the ascending aorta and into the LSA. The Aortic Component was tracked into place, and the device was then torqued to ensure the portal was properly aligned with the LSA ostium. After achieving the desired alignment, the Aortic Component was deployed. The GORE DrySeal Side Branch Introducer Sheath was advanced over the wire, and tracked easily through the tortuous anatomy. The Side Branch Component was advanced through this



## CASE IMAGES

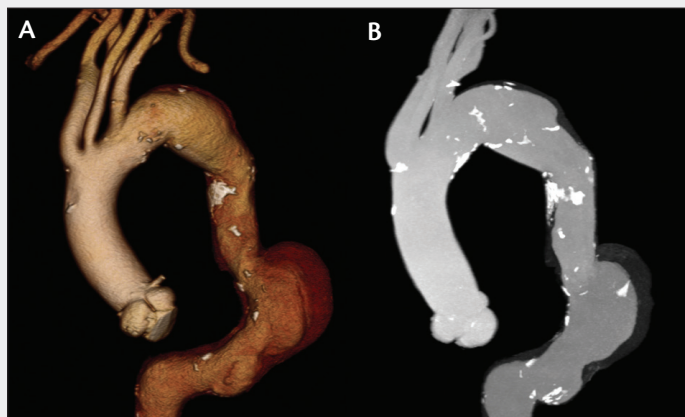


Figure 3. A 3-D (A) and 2-D (B) preoperative CT.

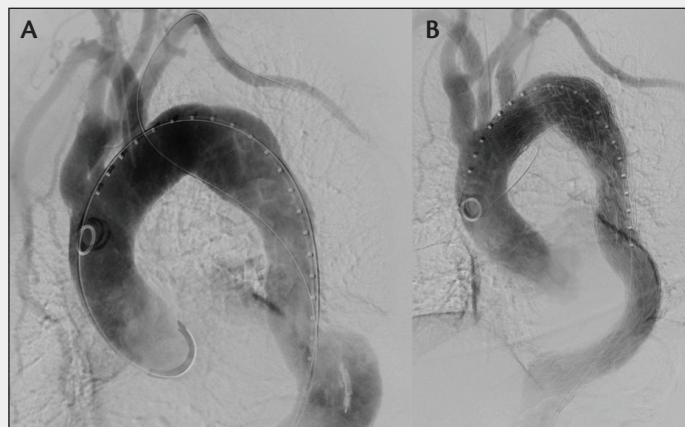


Figure 4. An initial procedural aortogram of the patient's anatomy (A) and a final aortogram of the device showing successful exclusion of the aneurysm (B).

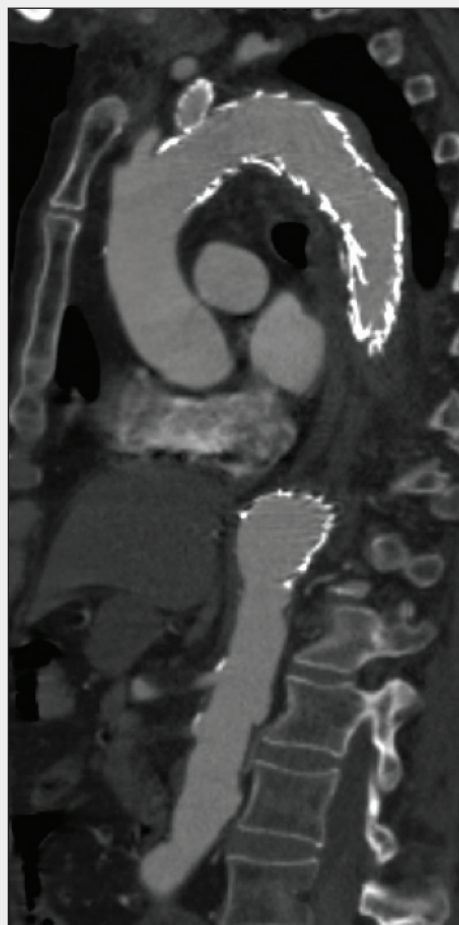


Figure 6. Postoperative CT scan.

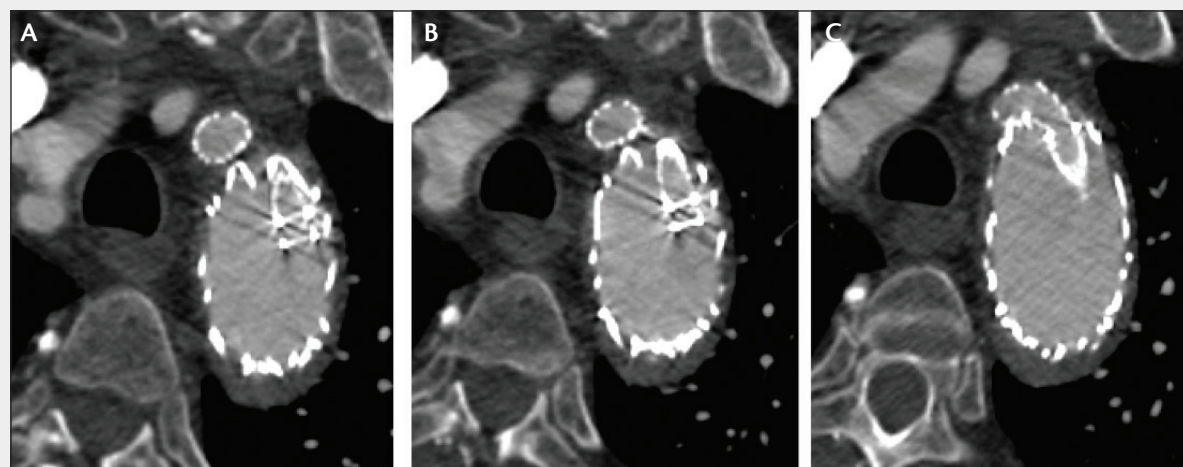


Figure 5. Postoperative CT axial slices of the GORE TAG Thoracic Branch Device focusing on the side branch.

sheath, the sheath was withdrawn, and the Side Branch Component was positioned in line with the portal, and deployed. Because the total treatment length was 27 cm, the traditional Conformable GORE TAG Device was implanted to extend coverage distally. Figure 4 shows an initial aortogram of the patient anatomy and a final aortogram after device deployments, showing successful exclusion of the aneurysm. At one month, CT follow-up showed a patent Side Branch perfusing the LSA and thrombosis of the aneurysm sac around the distal device (Figures 5 and 6).

## CONCLUSION

The GORE TAG Thoracic Branch Device has potential to provide an entirely endovascular approach to Zone 2 aneurysms, which has previously been an anatomical presentation necessitating surgical involvement. Anticipated application of the technology for other Zone 2 patholo-

gies (eg, dissection, trauma) and more proximal Zone 1 and 0 aortic disease awaits further clinical trial outcomes and FDA guidance. ■

*Michael D. Dake, MD, is the Thelma and Henry Doelger Professor (III) in the Department of Cardiothoracic Surgery at Stanford University School of Medicine and Falk Cardiovascular Research Center in Stanford, California. He has disclosed that he is a member of the scientific advisory board for Abbott Vascular, is a member of the medical advisory board for Gore & Associates, and is a consultant to Cook Medical and Medtronic. Dr. Dake may be reached at [mddake@stanford.edu](mailto:mddake@stanford.edu).*

1. Chung J, Kasirajan K, Veeraswamy RK, et al. Left subclavian artery coverage during thoracic endovascular aortic repair and risk of perioperative stroke or death. *J Vasc Surg*. 2011;54:979-984.

2. Buth J, Harris PL, Hobo R, et al. Neurologic complications associated with endovascular repair of thoracic aortic pathology: incidence and risk factors. a study from the European collaborators on stent/graft techniques for aortic aneurysm repair (EUROSTAR) registry. *J Vasc Surg*. 2007;46:1103-1110.

# The Use of TEVAR in Acute Uncomplicated Type B Aortic Dissection

Data and perspectives on the utility of endovascular repair in this challenging pathology.

BY GUIDO H.W. VAN BOGERIJEN, MD, AND HIMANSHU J. PATEL, MD

**T**horacic endovascular aneurysm repair (TEVAR) is a lifesaving therapy and currently the preferred treatment modality for patients with Type B aortic dissection presenting with complications such as aortic rupture or malperfusion syndrome.<sup>1-4</sup> Its role to treat uncomplicated acute Type B aortic dissection (ABAD), however, is not yet fully clarified. Consensus has been established to manage ABAD with surveillance and optimal medical treatment (OMT) with control of hypertension and heart rate.<sup>5,6</sup> Despite adequate antihypertensive treatment, however, delayed aortic dilatation will develop in 20% to 50% of patients with uncomplicated ABAD, which can lead to aortic rupture or late-term complications.<sup>2,7</sup> Attempts have been made to evaluate the use of early aortic repair compared to conventional medical therapy in uncomplicated ABAD with the ADSORB trial.<sup>8,9</sup>

## ADSORB TRIAL

The ADSORB trial is the first randomized controlled trial on acute aortic dissection and compares OMT with OMT plus TEVAR, performed with the aim to cover the primary entry tear in patients with uncomplicated ABAD.<sup>8,9</sup> Important exclusion criteria of this study were retrograde extension of dissection proximal to the left subclavian artery and presence of a connective tissue disorder. Primary endpoint was a combination of the following variables: (1) incomplete/no false lumen (FL) thrombosis; (2) aortic dilatation ( $\geq 5$  mm/year or descending aorta  $\geq 55$  mm); or (3) aortic rupture at one year.<sup>9</sup> One-year results demonstrated that thrombosis of the FL and reduction of its diameter are induced by the stent-graft in uncomplicated ABAD patients, but long-term results are needed.<sup>8</sup> Given the small sample size and duration of follow-up, the trial is not powered to detect differences in aortic-related and all-cause mortality.

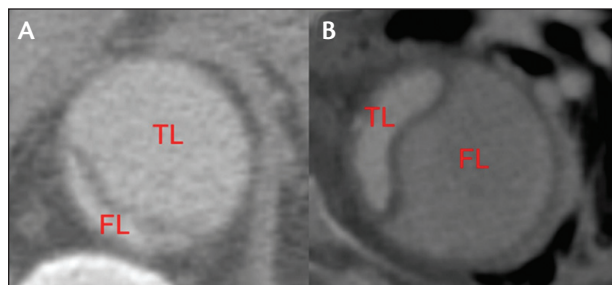
Therefore, a larger prospective, randomized, controlled trial with longer follow-up should be conducted to assess the preferred treatment modality for uncomplicated ABAD.

## INSTEAD TRIAL

The INSTEAD trial was the original study that compared medical management alone with additional TEVAR for long-term outcomes in uncomplicated subacute and early chronic type B aortic dissection.<sup>10</sup> The rationale behind this randomized trial is that coverage of the primary entry tear with a stent-graft will induce FL thrombosis and aortic remodeling. Despite this potential benefit, TEVAR may nevertheless be associated with complications, including aortic rupture, retrograde dissection, endoleaks, and stent-graft migration; therefore, a conservative approach in many patients is still advocated.

In the INSTEAD trial, patients with uncomplicated type B aortic dissection were randomly assigned to TEVAR in addition to OMT between 2 and 52 weeks from symptom onset. Patients were unsuitable for randomization in the presence of an aortic diameter  $> 55$  mm or with other emerging recurrent complications.<sup>10</sup> TEVAR in addition to OMT was associated with adverse early survival at two years and adverse event rates, despite favorable aortic remodeling.<sup>10</sup> This excess early mortality was mainly attributable to periprocedural deaths. In contrast, improved five-year aorta-specific survival and delayed disease progression was found.<sup>11</sup> Congruently, data from the International Registry of Acute Aortic Dissection (IRAD) showed improved late mortality if TEVAR was performed in addition to OMT, while similar results were seen between groups regarding early mortality.<sup>12</sup> The INSTEAD trial suggests that OMT and surveillance were associated with failure to prevent late complications, including aneurysmal growth, rupture, and late conver-



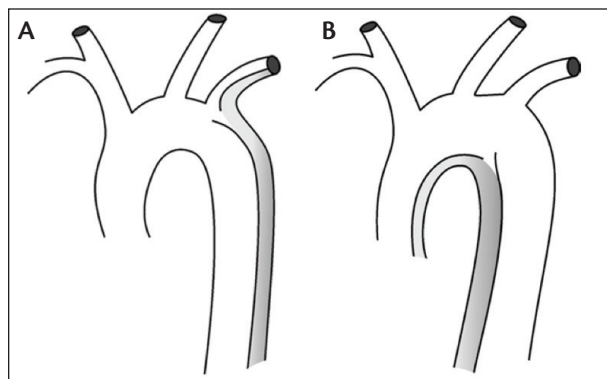


**Figure 1.** Computed tomography images show the configuration of the TL and FL. A circular-shaped TL is shown (A). An elliptic shape results when the FL compresses the TL (B). Adapted from *J Vasc Surg*, Volume 58, Tolenaar et al, Morphologic predictors of aortic dilatation in type B aortic dissection, pages 1220-1225, Copyright 2013, with permission from Elsevier.<sup>17</sup>

sion to emergent TEVAR, conveying a higher aorta-specific mortality. Thus, initial clinical stability ("uncomplicated") does not preclude emergent silent expansion and even rupture, and both events might be preventable by TEVAR in the early phase. Therefore, preemptive TEVAR should be considered in stable Type B dissection with suitable anatomy to avoid late complications. OMT alone may delay progressive aortic expansion, at best; conversely, TEVAR induces aortic remodeling. It should be noted that the INSTEAD trial included patients undergoing TEVAR in the subacute and early chronic phase, and therefore, their results cannot be completely generalized for the acute phase of Type B aortic dissection. Larger randomized, controlled trials should be established to address this open issue.

### CLINICAL AND RADIOLOGICAL PREDICTORS OF AORTIC GROWTH

To identify a cohort of uncomplicated ABAD patients at high risk for aortic growth and subsequent aortic rupture, several studies have been conducted.<sup>13-17</sup> Certain clinical and radiological predictors of aortic growth in ABAD patients have been identified (Table 1).<sup>18</sup> Recently, Tolenaar and colleagues found that the number of entry tears at initial imaging was associated with aortic growth during follow-up.<sup>19</sup> Patients with one entry tear at presentation showed a higher growth rate compared to patients with multiple entry tears.<sup>19</sup> The presence of only one patent entry tear might pressurize the FL and change the normal laminar flow into turbulent flow, leading to higher stress of the aortic wall and, due to a weakened dissected aortic wall, also to aortic enlargement. Additionally, Evangelista and colleagues demonstrated that patients with a primary entry tear  $\geq 10$  mm in the proximal part of the dissection presented more



**Figure 2.** Scheme of different sites of the primary entry tear of acute Type B aortic dissections (A). Primary entry tear at the outer circumference of the distal aortic arch defined as "convex." The retrograde component of the dissection is stopped by the left subclavian artery (B). Primary entry tear at the inner circumference of the distal aortic arch defined as "concave," allowing progression of the retrograde component of the dissection into the aortic arch and the ascending aorta. Adapted from *Ann Thorac Surg*, Volume 93, Loewe et al, A new mechanism by which an acute type B aortic dissection is primarily complicated, becomes complicated, or remains uncomplicated, pages 1215-1222, Copyright 2012, with permission from Elsevier.<sup>20</sup>

frequently with dissection-related events and experienced a higher growth rate than those with an entry tear  $< 10$  mm.<sup>13</sup> A larger tear size suggests that more blood enters the FL, causing increased FL pressurization and subsequent aortic enlargement. Interestingly, in the majority of patients, at least three-year follow-up was required before complications occurred, which indicates that structural and hemodynamic changes in the aortic wall and aorta require time to appear.<sup>13</sup>

Different radiologic predictors, including patent FL, FL diameter  $> 22$  mm, elliptic true lumen (TL) combined with round FL (Figure 1), one entry tear, and entry tear size  $> 10$  mm all seem interrelated due to pressurization of the FL, with subsequent aortic growth of the dissected segment.<sup>17,18</sup> Recent studies have shown that those patients with an entry tear at the concavity/undersurface of the distal aortic arch have more frequent development of complications (Figure 2).<sup>20,21</sup> This cohort of patients at high risk for aortic growth might benefit from closer follow-up and early intervention, even if those patients initially presented without complications. This approach deserves even more consideration because a significant number of patients will develop aneurysmal degeneration along the dissected segments during follow-up, and may lose the opportunity for endovascular treatment if not identified at an early stage.<sup>18</sup>

TABLE 1. PREDICTORS OF AORTIC GROWTH IN UNCOMPLICATED TYPE B AORTIC DISSECTION

	Predictor	Negative Predictor
Patient characteristics	Age < 60 y	Increasing age ( $\geq 60$ y)
	White race	
	Heart rate $\geq 60$ bpm	Heart rate < 60 bpm
Medical history	Marfan syndrome	
Clinical information		Use of calcium-channel blockers
Blood test	FDP level $\geq 20$ $\mu\text{g/mL}$ on admission	
Radiologic signs	Aortic diameter $\geq 40$ mm during acute phase	Diameter < 40 mm (debated)
	Patent FL	Closed/thrombosed FL
	Partially thrombosed FL (debated)	
	Proximal descending thoracic aorta FL diameter ( $\geq 22$ mm) on initial imaging	
		IMH
	Sac formation in partially thrombosed FL	
	One entry tear	Increased number of entry tears
	FL/intimal tear located at the inner aortic curvature	FL/intimal tear located at the outer curvature
	An elliptic configuration of the TL/round configuration FL	A circular configuration of the TL/elliptic configuration FL
	Areas with localized dissection/ULP	
	Degree of fusiform dilatation of the proximal descending aorta (FI $\geq 0.64$ )	FI < 0.64
	Large entry tear ( $\geq 10$ mm) located in the proximal part of the dissection	

Abbreviations: BPM, beats per minute; FDP, fibrinogen-fibrin degradation product; FI, fusiform index; FL, false lumen; IMH, intramural hematoma; TL, true lumen; ULP, ulcer-like projections.

Adapted from J Vasc Surg, Volume 59, van Bogerijen GH et al, Predictors of aortic growth in uncomplicated type B aortic dissection, pages 1134-1143, Copyright 2014, with permission from Elsevier.<sup>18</sup>

## RETROGRADE TYPE A DISSECTION

Retrograde Type A dissection is a feared complication after TEVAR and is one of the factors limiting the routine use of this treatment modality for uncomplicated ABAD.<sup>22</sup> Despite its rare occurrence (estimated 1%–2%), it has a high risk of mortality (around 40%).<sup>22</sup> Considering other stent-graft-related complications such as endoleaks and stent-graft migration, further modification of current device design and endovascular approach is warranted.

## FUTURE PERSPECTIVES

To assess the management controversies of uncomplicated ABAD, larger randomized, controlled trials should be conducted. The timing of the procedure is especially of interest in studies about uncomplicated Type B dissection and can be classified into acute (0–2 weeks); subacute (2–8 weeks), and chronic Type B dissection (> 8 weeks).<sup>23</sup> Other temporal classifications have also been used. Recently, the IRAD registry described a new temporal classification system of acute dissection

based on survival curves demonstrating that survival decreases significantly up to 30 days after presentation, with chronic dissection defined > 30 days after symptom onset.<sup>24</sup> A recent European multidisciplinary expert group defined acute Type B dissection as < 2 weeks, sub-acute 2 to 6 weeks, and chronic > 6 weeks from symptom onset.<sup>25</sup> Taking into consideration these and other temporal classification systems, an updated consensus definition of dissection acuity based on survival and aortic event rates, as well as the temporal relationship between the aortic remodelling after endovascular therapy and dissection chronicity is needed. Studies should be focused also on early and late outcomes related to the timing of TEVAR, either in the acute, subacute, or chronic phase.

Over the last year, the United States Food and Drug Administration approved both the Conformable Gore® TAG® Thoracic Endoprosthesis (Gore & Associates) and Valiant Thoracic Stent Graft (Medtronic, Inc.) devices for the treatment of acute and chronic, complicated and uncomplicated, Type B aortic dissections. However, the clinical trials leading to approval of the devices included only acute, complicated Type B dissection cases. Robust data to support the indication of TEVAR for uncomplicated ABAD are not currently present, and future studies will help determine appropriate therapeutic pathways.

*Acknowledgements: This work was generously supported by David L. Hamilton and the Phil Jenkins Breakthrough Fund in Cardiac Surgery.*

*Guido H.W. van Bogerijen, MD, is with the Department of Cardiac Surgery, University of Michigan Cardiovascular Center in Ann Arbor, Michigan. He has disclosed that he has no financial interests related to this article.*

*Himanshu J. Patel, MD, is Associate Professor of Cardiac Surgery, Department of Cardiac Surgery, University of Michigan Cardiovascular Center in Ann Arbor, Michigan.*

*He has disclosed that he has a consulting relationship and patent with Gore & Associates. Dr. Patel may be reached at (734) 615-9129; hjpatel@med.umich.edu.*

1. Dake MD, Kato N, Mitchell RS, et al. Endovascular stent-graft placement for the treatment of acute aortic dissection. *N Engl J Med*. 1999;340:1546-1552.
2. Fattori R, Tsai TT, Myrmel T, et al. Complicated acute type B dissection: is surgery still the best option?: a report from the International Registry of Acute Aortic Dissection. *JACC Cardiovasc Interv*. 2008;1:395-402.
3. Lombardi JV, Cambria RP, Nienaber CA, et al. Prospective multicenter clinical trial (STABLE) on the endovascular treatment of complicated type B aortic dissection using a composite device design. *J Vasc Surg*. 2012;55:629-640 e2.
4. Nienaber CA, Kische S, Ince H, Fattori R. Thoracic endovascular aneurysm repair for complicated type B aortic dissection. *J Vasc Surg*. 2011;54:1529-1533.
5. Golledge J, Eagle KA. Acute aortic dissection. *Lancet*. 2008;372:55-66.
6. Tolenaar JL, van Bogerijen GH, Eagle KA, Trimarchi S. Update in the management of aortic dissection. *Curr Treat Options Cardiovasc Med*. 2013;15:200-213.
7. Umaña JP, Lai DT, Mitchell RS, et al. Is medical therapy still the optimal treatment strategy for patients with acute type B aortic dissections? *J Thorac Cardiovasc Surg*. 2002;124:896-910.
8. Brunkwall J, Kasprzak P, Verhoeven E, et al. Endovascular repair of acute uncomplicated aortic type B dissection promotes aortic remodelling: 1 year results of the ADSORB trial. *Eur J Vasc Endovasc Surg*. 2014;48:285-291.
9. Brunkwall J, Lammer J, Verhoeven E, Taylor P. ADSORB: a study on the efficacy of endovascular grafting in uncomplicated acute dissection of the descending aorta. *Eur J Vasc Endovasc Surg*. 2012;44:31-36.
10. Nienaber CA, Rousseau H, Eggebrecht H, et al. Randomized comparison of strategies for type B aortic dissection: the Investigation of Stent Grafts in Aortic Dissection (INSTEAD) trial. *Circulation*. 2009;120:2519-2528.
11. Nienaber CA, Kische S, Rousseau H, et al. Endovascular repair of type B aortic dissection: long-term results of the randomized investigation of stent grafts in aortic dissection trial. *Circ Cardiovasc Interv*. 2013;6:407-416.
12. Fattori R, Montgomery D, Lovato L, et al. Survival after endovascular therapy in patients with type B aortic dissection: a report from the International Registry of Acute Aortic Dissection (IRAD). *JACC Cardiovasc Interv*. 2013;6:876-882.
13. Evangelista A, Salas A, Ribera A, et al. Long-term outcome of aortic dissection with patent false lumen: predictive role of entry tear size and location. *Circulation*. 2012;125:1133-1141.
14. Jonker FH, Trimarchi S, Rampoldi V, et al. Aortic expansion after acute type B aortic dissection. *Ann Thorac Surg*. 2012;94:1223-1229.
15. Kato M, Bai H, Sato K, et al. Determining surgical indications for acute type B dissection based on enlargement of aortic diameter during the chronic phase. *Circulation*. 1995;92:1107-1112.
16. Song JM, Kim SD, Kim JH, et al. Long-term predictors of descending aorta aneurysmal change in patients with aortic dissection. *J Am Coll Cardiol*. 2007;50:799-804.
17. Tolenaar JL, van Keulen JW, Jonker FH, et al. Morphologic predictors of aortic dilatation in type B aortic dissection. *J Vasc Surg*. 2013;58:1220-1225.
18. van Bogerijen GH, Tolenaar JL, Rampoldi V, et al. Predictors of aortic growth in uncomplicated type B aortic dissection. *J Vasc Surg*. 2014;59:1134-1143.
19. Tolenaar JL, van Keulen JW, Trimarchi S, et al. Number of entry tears is associated with aortic growth in type B dissections. *Ann Thorac Surg*. 2013;96:39-42.
20. Loewe C, Czerny M, Sodeck GH, et al. A new mechanism by which an acute type B aortic dissection is primarily complicated, becomes complicated, or remains uncomplicated. *Ann Thorac Surg*. 2012;93:1215-1222.
21. Weiss G, Wolner I, Folkmann S, et al. The location of the primary entry tear in acute type B aortic dissection affects early outcome. *Eur J Cardiothorac Surg*. 2012;42:571-576.
22. Eggebrecht H, Thompson M, Rousseau H, et al. Retrograde ascending aortic dissection during or after thoracic aortic stent graft placement: insight from the European registry on endovascular aortic repair complications. *Circulation*. 2009;120:5276-5281.
23. Wilkinson DA, Patel HJ, Williams DM, et al. Early open and endovascular thoracic aortic repair for complicated type B aortic dissection. *Ann Thorac Surg*. 2013;96:23-30; discussion 230.
24. Boher AM, Isselbacher EM, Nienaber CA, et al. The IRAD classification system for characterizing survival after aortic dissection. *Am J Med*. 2013;126:730 e19-24.
25. Fattori R, Cao P, De Rango P, et al. Interdisciplinary expert consensus document on management of type B aortic dissection. *J Am Coll Cardiol*. 2013;61:1661-1678.



# A New Angle on Precise Endograft Placement

The potential benefits of orthogonal device placement in angulated aortic necks.

BY CONSTANTINO S. PEÑA, MD, AND BARRY T. KATZEN, MD

**A**bdominal aortic aneurysms (AAAs) are treated using endografts now more than ever. The ability to successfully perform endovascular abdominal aortic aneurysm repair (EVAR) depends on several key factors. The nature of the proximal aortic infrarenal neck is an essential component in predicting how successful EVAR will be. Conquering the proximal neck is likely the most important consideration in predicting an immediate, as well as long-term, successful outcome after EVAR.

Traditionally, the proximal infrarenal neck should be  $\geq 15$  mm in length,  $< 32$  mm in diameter, and uniform in diameter throughout its length. The neck should be morphologically free of thrombus and calcification. Additionally, the neck should be straight to allow maximal coverage by the proximal graft. The endovascular treatment of AAAs in patients with angulated necks, both moderate and severe, remains one of the great challenges of EVAR. In our own practice, around 20% to 40% of all patients have significant angulation of the neck ( $> 60^\circ$ ).

## CHALLENGES OF ANGULATED NECKS

When patients with angulated infrarenal aortic necks have other unfavorable characteristics such as reduced neck lengths, enlarged neck diameter, or circumferential thrombus, successful treatment becomes even more challenging. These infrarenal neck characteristics further increase the degree of difficulty of the EVAR procedure. The proximal portion of the covered stent serves as the seal of the graft to the proximal aorta. Failure to achieve optimal and complete apposition of the endograft to the vessel wall is likely to have poor results with a higher probability of developing a Type 1A endoleak in both the short- and long-term.

The endovascular treatment of AAAs in patients with angulated necks is difficult because the placement of the proximal graft along the true center of the aorta is mechanically difficult. Typically, the effective length

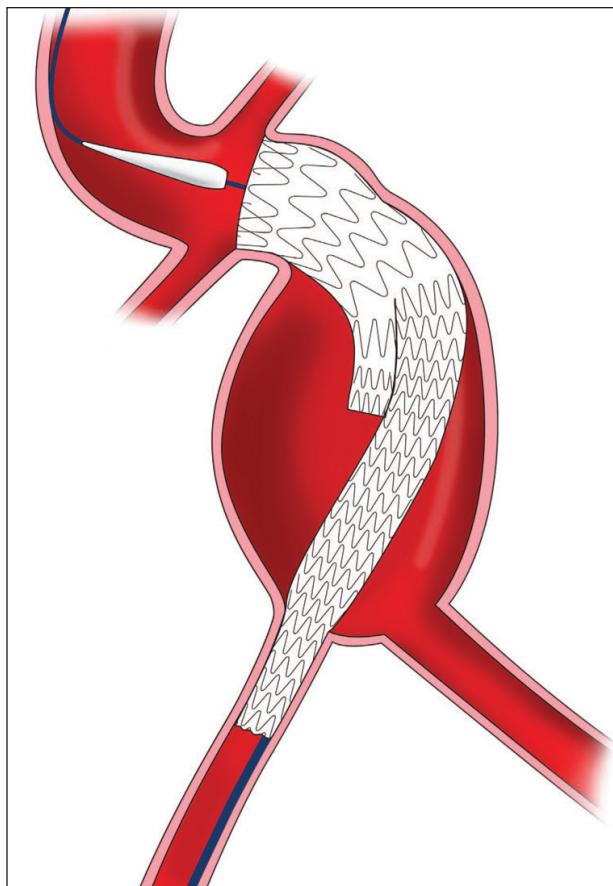of the infrarenal neck is minimized because the graft deploys horizontally to the angled aorta as opposed to horizontal to the center line or true lumen of the aorta. When the graft deploys straight across the aorta with effectively little compensation for the angle of the aortic lumen, the length of the infrarenal neck sealing is minimized. The graft is usually seated asymmetrically in respect to the aortic neck with a shortened portion of the neck length serving as part of the endograft's proximal seal.

In the scenario of a patient with an angulated proximal infrarenal neck needing EVAR with a challenged proximal aortic seal, operators may need to use additional devices such as proximal cuffs, balloon-expandable stents, and endoanchors in order to improve the resulting poor proximal aortic neck apposition and sealing. Clearly, one of the unmet clinical needs in EVAR technology is the ability to predictably achieve maximal primary fixation and sealing in an angulated neck without the need for immediate or secondary interventional procedures.

Currently at our institution, the presence of an angulated neck is not an exclusion criterion for endovascular therapy in isolation; however, it is a predictor of a challenging procedure with a higher risk of needing other therapies for endoleaks. In a recent study evaluating the M2S database, patients treated outside of the instructions for use with angulated, short, or dilated proximal aortic necks had a higher rate of secondary procedures and unsuccessful repairs (defined as aortic sac enlargement).<sup>1</sup>

## TECHNIQUES FOR TREATING ANGULATED NECKS

Several procedural tricks have been attempted to maximize aortic sealing in patients with angulated necks. The removal of the stiff guidewire or exchange for a soft guidewire from the graft delivery device immediately before deployment of the graft can allow



**Figure 1.** The ability to angulate the proximal portion of the endograft can allow sealing perpendicular to the aortic lumen, allowing maximal proximal neck apposition.

the proximal graft to better conform to the true center of the vessel. Also, a more aggressive technique to maximize the seal within the neck of an angulated aortic neck has included the use of a renal artery balloon from an upper extremity approach to buttress or serve as an “endowedge” on which the operator delivers the forward force of the delivery sheath and graft during deployment. Unfortunately, these techniques are usually not very helpful in angulated necks because of the inherent stiffness of the device delivery shaft, which only significantly aids the amount of sealing in a few patients.

Ideally, in an angulated infrarenal neck, the operator would have the ability to position an endograft along the centerline of blood flow (the angle of the angulation) in order to optimize the apposition of covered stent fabric throughout the length and circumference of the infrarenal neck. Currently, the endograft's deployment in an angulated neck generally results in the endograft's plane not matching the plane of the neck's angulation, result-

ing in placement of the superior aspect of the covered stent asymmetrically below the start of the infrarenal neck and the subsequent loss of 2 to 5 mm of possible apposition.

Orthogonal placement (perpendicular to the flow lumen) of an infrarenal endograft would maximize the amount of infrarenal graft apposition to the aortic wall, producing both excellent fixation and sealing (Figure 1).

What are the ideal characteristics of an endograft to maximize orthogonal placement in an angulated neck? In order to properly accommodate orthogonal placement in an angled aortic neck, the ideal endograft would not require a suprarenal component. Stent-graft fixation itself can be accomplished either with a suprarenal or infrarenal graft with similar acute and long-term results. The infrarenal device would maximize its seal by being able to conform along the flow direction of the vessel at the level of the neck. The endograft should be flexible in order to conform. The lack of a suprarenal component should improve its flexibility. Once in position, the endograft should be durable and stable in that position, due to active infrarenal fixation.

### **GORE® EXCLUDER® CONFORMABLE AAA ENDOPROSTHESIS\***

The delivery system of the GORE EXCLUDER Conformable Device is intended to provide a unique solution to neck angulation through a number of unique benefits:

1. When the device is constrained on the delivery catheter, it can be angulated at the proximal end. This feature is intended to achieve proximal endograft positioning along the centerline of blood flow or orthogonal to the flow lumen.
2. The GORE EXCLUDER Conformable Device can also be angulated while it is partially deployed, providing another opportunity to align the endograft to be orthogonal to blood flow.
3. Similar to the GORE® EXCLUDER® Device featuring the C3® Delivery system, the GORE EXCLUDER Conformable Device can be constrained and reopened at the proximal end, which is intended to allow precise positioning in the proximal and distal portions of the neck. Another significant advantage of this feature is that it allows for optimal device positioning when cannulating the contralateral gate.

All of these delivery system characteristics, combined with a conformable endograft, are intended to provide marked improvement and operator control in the treatment of AAAs with angulated necks.

## CONCLUSION

As we attempt to better treat our patients with angled necks, a device that is designed to be conformable, reconstrainable, and accurately positioned to maximize the aortic neck coverage will provide more opportunity to achieve optimal seal and fixation for a successful, long-term AAA repair. ■

*Constantino S. Peña, MD, is an interventional radiologist and Medical Director of Vascular Imaging at Miami Cardiac and Vascular Institute in Miami, Florida. He has disclosed that he is on the advisory board for Bard*

*Peripheral Vascular and Boston Scientific Corporation, receives a teaching honorarium from Cook Medical, and receives research support from Gore & Associates. Dr. Peña may be reached at [tinopena@msn.com](mailto:tinopena@msn.com).*

*Barry T. Katzen, MD, is Founder and Medical Director of Miami Cardiac and Vascular Institute in Miami, Florida. He has disclosed that he is on the advisory board for Gore & Associates, Medtronic, and Boston Scientific Corporation.*

1. Schanzer A, Greenberg RK, Hevelone N, et al. Predictors of abdominal aortic aneurysm sac enlargement after endovascular repair. *Circulation*. 2011;123:2848-2855.



# Taking Advantage of Opportunities to Maximize Infrarenal Seal

Advantages and applicability of the GORE® C3® Delivery System.

BY ROBERT Y. RHEE, MD

Endovascular repair (EVAR) for abdominal aortic aneurysms (AAAs) has become the standard of care, with low perioperative morbidity and mortality.<sup>1,2</sup> As physicians have become more skilled in the adaptation of this technology, the treatment range has been greatly extended to include patients with challenging anatomies. Central to successful EVAR in less-than-ideal anatomic situations is the precise placement of the device to maximize infrarenal seal. The use of a truly repositionable endograft is paramount both in teaching applications and in successful repair of challenging anatomy by maximizing deployment accuracy, potentially reducing procedure and fluoroscopy time, and providing cost savings in the form of reduced usage of additional components.

## ADVANTAGES OF THE GORE® EXCLUDER® AAA ENDOPROSTHESIS AND GORE® C3® DELIVERY SYSTEM

The GORE EXCLUDER AAA Endoprosthesis featuring C3 Delivery System (Gore & Associates) was developed by the company in cooperation with experienced users. This system was borne out of a true clinical need for precise and adjustable deployment in less-than-ideal anatomic situations for EVAR that most clinicians face in today's modern aortic practices. With this unique deployment system, the operator can reposition the stent-graft to achieve optimal fixation and sealing within the limitations of the patient's hostile anatomy.<sup>3</sup>

Deployment with this system is a simple, three-step process, which includes the option

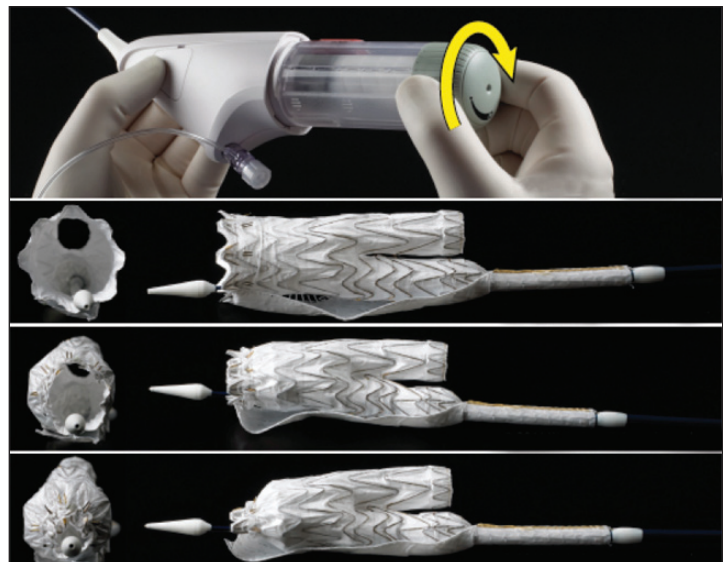

Figure 1. The system can be constrained to enable repositioning. Slowly constrain the proximal end, reposition the trunk, then slowly reopen to engage the proximal anchors.

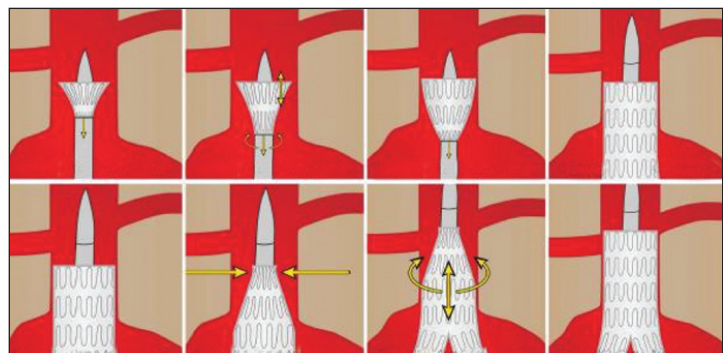


Figure 2. The system allows up to three opportunities to reposition for precise placement.

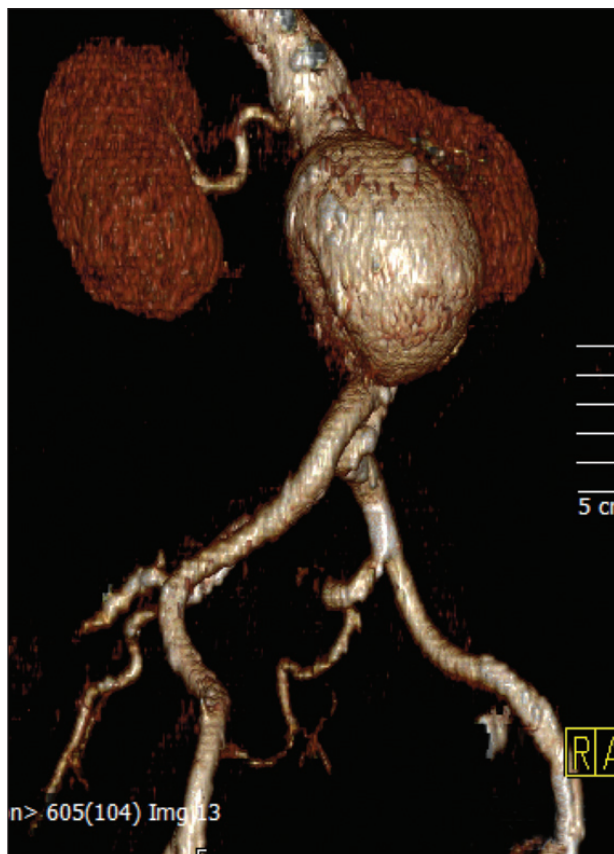

Figure 3. CTA of a patient with a short, angulated neck and an 8-cm AAA.

of reconstraining and repositioning the device (Figure 1). This allows for user-desired adjustments for both the level of the device for precise placement and orientation of the contralateral limb to ease gate cannulation. First, the body and contralateral limb of the device are opened. If desired, a constraining loop around the body of the graft allows for reconstraint of the device. After controlled positioning, the graft can then be unconstrained (Figure 2). These steps can be repeated up to two times. Once positioning is satisfactory, the constraining loop is removed, and the ipsilateral limb is opened to complete deployment.

### CLINICAL CHALLENGES

Despite advancements in stent-graft technology, severely angulated or short necks (Figure 3) remain a significant challenge to successful endovascular treatment and are the most common reasons EVAR may not be a feasible option.<sup>4,5</sup> As long as proper technique and optimized devices (e.g. hydrophilic sheaths and low-profile EVAR devices) are used, however, good outcomes are not impossible, and there are increasing

numbers of successful cases being reported with reasonable long-term outcomes.<sup>6-8</sup>

### Short Necks

Although proximal neck lengths between 10 mm and 15 mm can be treated with most stent-grafts,<sup>8,9</sup> a standardized neck length requirement for the best long-term results, regardless of the device used, still has yet to be determined. Depending on the device's design, the ideal length requirements vary. Stent-grafts that have active fixation with metal struts that penetrate the aorta tend to do well in short necks,<sup>10,11</sup> although the quality of the neck (e.g. hostile neck features such as excessive thrombus or calcium, which can lead to poor outcomes) should be assessed, because the neck length is not the only determinant in accurate deployment or long-term success. Ideally, a stent-graft system's design should allow it to seal within 1 mm or less of the most distal renal artery and be able to take advantage of every millimeter of proximal neck for the greatest likelihood of long-term success (Figures 4–6).

### Angulated Necks

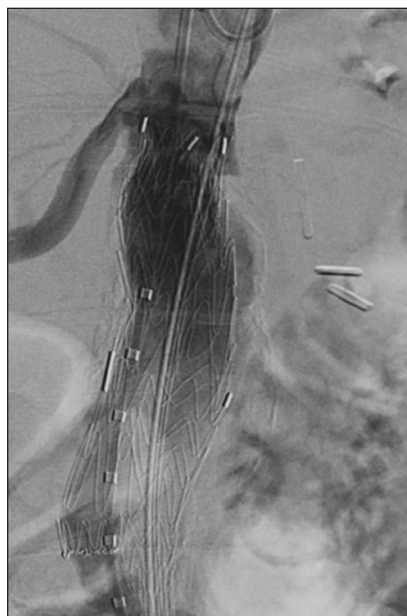
The current-generation stent-grafts were mainly designed for straight-neck sealing zones. Most devices are not engineered to seal in necks > 60°. The indications do not consider concurrent hostile neck characteristics—including short necks < 15 mm, reverse taper of > 30%, or extensive thrombus or calcium—which reduce the likelihood of successful long- and short-term outcomes. As previously mentioned, the presence of more than one hostile neck characteristic further necessitates precise device placement to facilitate procedural success.

### Tight Access

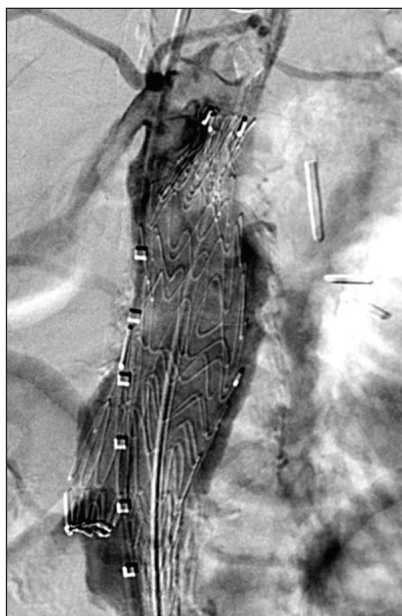
The GORE® DrySeal Sheath with hydrophilic coating has revolutionized difficult access issues because this sheath allows the operator to traverse almost any access environment. The sheath is designed to increase lubricity and minimize coating particulation to make for easier insertion and removal. The sheath's valve is pressurized to create a seal, which minimizes blood loss while still accommodating multiple wires and catheters. Gore has also reduced the device profile for the current-generation stent systems down to 16 Fr for stent-grafts up to 26 mm, so the 28.5 mm, 31 mm, and 35 mm grafts are the only sizes that need an 18 Fr delivery system.

### Ease of Gate Cannulation

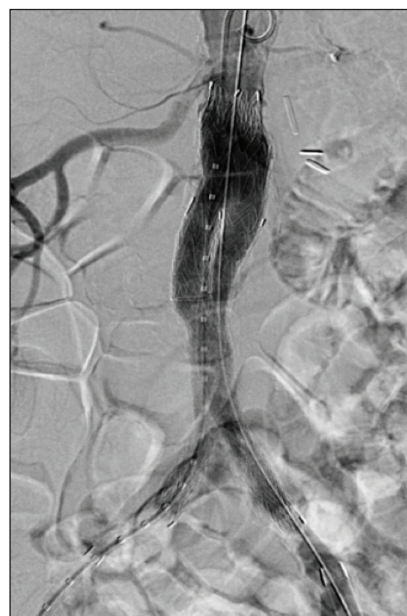Another significant factor in EVAR is contralateral leg gate cannulation, especially in large, open sacs or where



**Figure 4.** The GORE EXCLUDER AAA Endoprosthesis is initially deployed in a patient with an occluded left renal artery.



**Figure 5.** The Gore Excluder AAA Endoprosthesis is being repositioned and rotated to optimize the limited sealing zone of the infrarenal neck and to aid in cannulation because the contralateral gate is blocked by aortic plaque.



**Figure 6.** The GORE EXCLUDER AAA Endoprosthesis in final configuration.

there are aortic abnormalities such as lumen obstructions that can hinder cannulation (Figure 4). The ability to reposition the contralateral gate after initial deployment can significantly ease this process. The GORE C3 Delivery System makes these scenarios more navigable due to its ability to be reconstrained and repositioned to achieve an optimal proximal seal (Figure 5). This ease-of-use feature can also reduce procedure time, as well as fluoro time and exposure, which is beneficial to both the patient and physician.

#### Reduction in Aortic Extender Usage

Finally, the ability to maximize infrarenal seal with repositionability as desired can also have positive financial implications. The GORE EXCLUDER AAA Endoprosthesis featuring C3 Delivery system, can significantly reduce the need for proximal extension cuffs in patients with unfavorable aortic neck anatomy.<sup>12</sup> The Gore Global Registry for Endovascular Aortic Treatment (GREAT) was designed to evaluate real-world outcomes after treatment with aortic endovascular devices (the GORE EXCLUDER Device, GORE C3 Delivery System, GORE® TAG® Device, and Conformable GORE® TAG® Device)<sup>13,14</sup> used in global markets and to identify the trends of on- and off-label use of the devices.

Data collected from the Gore GREAT registry have shown that the introduction of the GORE C3 Delivery System resulted in a > 50% reduction in aortic extender usage and a > 33% reduction in overall extender usage (including iliac extenders), as compared to use with the GORE® SIM-PULL Delivery System.<sup>15</sup> Less unplanned extender usage is a clear benefit in both procedural time and from a case-cost standpoint.

#### GORE C3 DELIVERY SYSTEM IN A TEACHING APPLICATION

With EVAR becoming the standard of care for AAAs, it is important for fellows to be trained appropriately in this technique. Repositionable delivery provides an opportunity to teach this procedure, where suboptimal device placement is correctable without undue repercussions to patient safety. Gore also continues to work on profile reductions, such as with the new lower profile trunks, which provide benefits in patient inclusion and potentially reduced access complications.

The Gore C3 system allows the operator to confidently let the trainee deploy the stent-graft knowing the device can be repositioned. The system allows the trainee to perform the procedure without the irreversibility of other systems. Because of this fact, in



teaching environments, more difficult anatomies can be approached with the teaching aspect of this device always in the forefront.

## CONCLUSION

The GORE C3 Delivery System is an optimal device, both to fellows and those new to EVAR and to the experienced physician facing a complex case with challenging anatomy. Experience thus far has shown that the system provides advantages with its repositionability in standard and complicated cases alike. ■

*Robert Y. Rhee, MD, is Chief of Vascular and Endovascular Surgery and Director of the Maimonides Aortic Center in Brooklyn, New York. He has disclosed that he is a consultant to Gore & Associates and Boston Scientific Corporation and receives research support from Gore & Associates, Boston Scientific Corporation, and Medtronic. Dr. Rhee may be reached at [rrhee@maimonidesmed.org](mailto:rrhee@maimonidesmed.org).*

*Gore does not recommend treating patients with neck anatomy that does not comply with the following:*


- *Infrarenal aortic neck treatment diameter range of 19 – 32 mm and a minimum aortic neck length of 15 mm*

- *Proximal aortic neck angulation  $\leq 60^\circ$*
- *Please consult the Instructions for Use for complete indications, contraindications, warnings, and precautions.*


1. Lederle FA, Freischlag JA, Kyriakides TC, et al. Outcomes following endovascular vs open repair of abdominal aortic aneurysm: a randomized trial. *JAMA*. 2009;302:1535-1542.
2. Jackson RS, Chang DC, Freischlag JA. Comparison of long-term survival after open vs endovascular repair of intact abdominal aortic aneurysm among Medicare beneficiaries. *JAMA*. 2012;307:1621-1628.
3. Verhoeven EL, Oikonomou K, Möhner B, et al. First experience with the new repositionable C3 excluder stent-graft. *J Cardiovasc Surg (Torino)*. 2011;52:637-642.
4. Antoniou GA, Georgiadis GS, Antoniou SA, et al. A meta-analysis of outcomes of endovascular abdominal aortic aneurysm repair in patients with hostile and friendly neck anatomy. *J Vasc Surg*. 2013;57:527-538.
5. Stather PW, Sayers RD, Cheah A, et al. Outcomes of endovascular aneurysm repair in patients with hostile neck anatomy. *Eur J Vasc Endovasc Surg*. 2012;44:556-561.
6. Aburahma AF, Campbell JE, Mousa AY, et al. Clinical outcomes for hostile versus favorable aortic neck anatomy in endovascular aortic aneurysm repair using modular devices. *J Vasc Surg*. 2011;54:13-21.
7. Leurs LJ, Kievit J, Dagnelle PC, et al; EUROSTAR Collaborators. Influence of infrarenal neck length on outcome of endovascular abdominal aortic aneurysm repair. *J Endovasc Ther*. 2006;13:640-648.
8. Georgiadis GS, Trellopoulos G, Antoniou GA, et al. Early results of the Endurant endograft system in patients with friendly and hostile infrarenal abdominal aortic aneurysm anatomy. *J Vasc Surg*. 2011;54:616-627.
9. Hager ES, Cho JS, Makaroun MS, et al. Endografts with suprarenal fixation do not perform better than those with infrarenal fixation in the treatment of patients with short straight proximal aortic necks. *J Vasc Surg*. 2012;55:1242-1246.
10. Lee JT, Ullery BW, Zarins CK, et al. EVAR deployment in anatomically challenging necks outside the IFU. *Eur J Vasc Endovasc Surg*. 2013;46:65-73.
11. Katsargyris A, Verhoeven EL. Endovascular strategies for infrarenal aneurysms with short necks. *J Cardiovasc Surg (Torino)*. 2013;54(1 suppl 1):21-26.
12. Smeds MR, Jacobs DL, Peterson GJ, Peterson BG. Short-term outcomes of the C3 excluder for patients with abdominal aortic aneurysms and unfavorable proximal aortic seal zones. *Ann Vasc Surg*. 2013;27:8-15.
13. Verhoeven EL, Katsargyris A, Milner R. The GREAT registry: lessons learned from real-world experience with the GORE® C3® delivery system. *Endovasc Today*. 2013;12(suppl):4-6.
14. Bachoo P, Verhoeven EL, Larzon T. Early outcome of endovascular aneurysm repair in challenging aortic neck morphology based on experience from the GREAT C3 registry. *J Cardiovasc Surg (Torino)*. 2013;54:573-580.
15. Data combined from three IDE trials, one post-approval study. Complete data on file.

# Trusted Performance

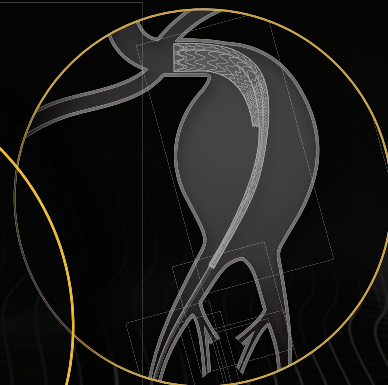TODAY and TOMORROW



TODAY  
GORE® EXCLUDER®  
AAA Endoprosthesis



TOMORROW  
Abdominal Conformable  
Stent-Graft\*



TOMORROW  
Abdominal Low Profile  
Stent-Graft\*

## Proven Now and Positioned for the Future

More than 15 years of worldwide **EXPERIENCE** and 190,000 devices distributed.

Proven **DURABILITY** backed by extensive clinical and commercial data\*\*.

More opportunities to optimize infrarenal seal with intuitive **REPOSITIONABLE** delivery system.

Learn more at [goremedical.com/aortic/evar](http://goremedical.com/aortic/evar)



EXCLUDER®

AAA ENDOPROSTHESIS

\* Products are under development and not available or approved for sale in any market.

\*\* Data on file.

Please see accompanying prescribing information in this journal.

W. L. Gore & Associates, Inc. • Flagstaff, AZ 86004 • [goremedical.com](http://goremedical.com)

Products listed may not be available in all markets.

GORE®, EXCLUDER®, PERFORMANCE BY DESIGN, and designs are trademarks of W. L. Gore & Associates.

© 2014, 2015 W. L. Gore & Associates, Inc. AT0913-EN3 MARCH 2015

PERFORMANCE  
by design

# Management of Aortoiliac Aneurysms: Preserve or Sacrifice the Hypogastric Artery?

Clinical experience with the GORE® EXCLUDER® Iliac Branch Endoprosthesis.\*

BY REZA GHOTBI, MD, AND SYLVIA SCHOENHOFER, MD

**M**ore than 30% of patients with abdominal aortic aneurysms have further aneurysmal changes in the common iliac artery or internal iliac artery.<sup>1</sup> Endovascular abdominal aortic aneurysm repair (EVAR) is frequently applied to a large variety of patients with aortoiliac aneurysms. The key question in the management of aortoiliac aneurysms is whether to preserve or sacrifice the hypogastric artery.

The EUROSTAR registry showed a significant risk for Type IB endoleak, reintervention, and rupture when aortoiliac aneurysms were treated with standard endografts.<sup>2</sup>

Current literature indicates the frequency and intensity of pelvic ischemia resulting from embolization or from covering of the hypogastric artery remain unpredictable, and upon onset, there is no standard solution for an

adequate technical repair.<sup>3,4</sup> In theory, the occlusion of the hypogastric artery can be well tolerated; however, in real life, the issue is more complex.

Different complications (e.g., buttock claudication, colitis, sexual dysfunction, and paraplegia) that can potentially occur after occlusion of the internal iliac artery can hardly be predicted or treated with standard procedures. In terms of individual treatment planning, it is in general agreement regarding these uncertain circumstances to preserve at least one hypogastric artery.<sup>5</sup> Iliac branched EVAR devices provide a completely endovascular method for treating extensive aortoiliac or iliac aneurysms (Figures 1, 2, and 3) while concomitantly preserving hypogastric artery flow. Iliac branched device technology has evolved over the past decade and has demonstrated a low complication rate both during and after the procedure.<sup>6</sup>

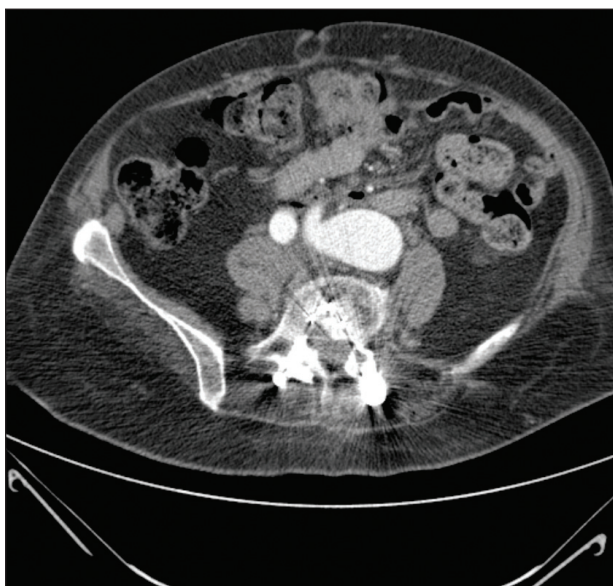

Figure 1. Preoperative computed tomography angiogram showing an isolated iliac aneurysm.

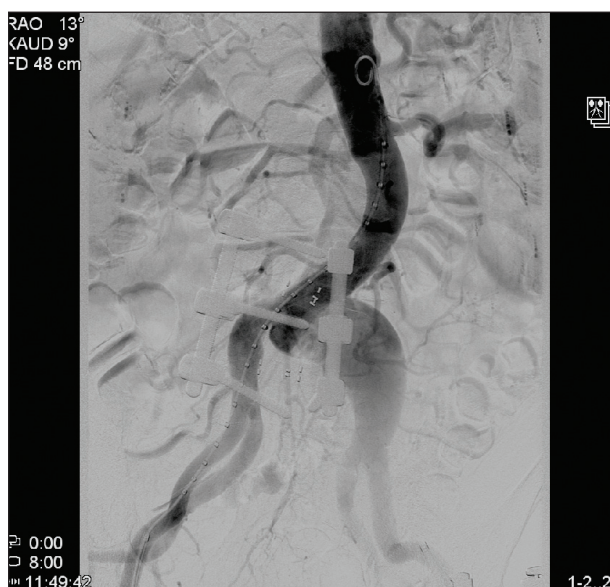
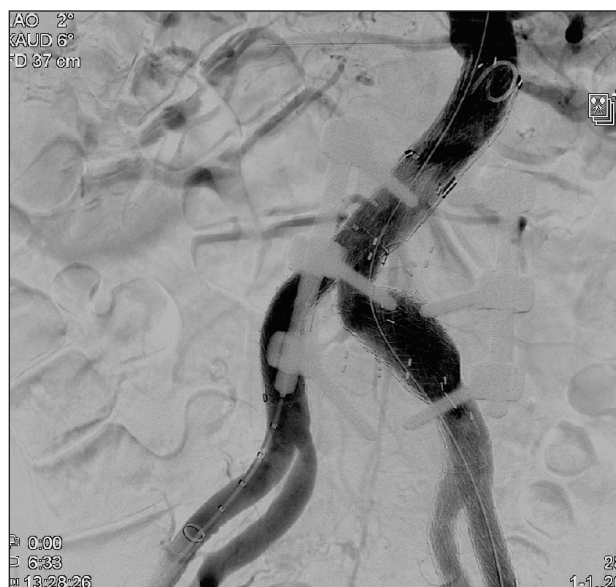


Figure 2. Intraoperative angiogram of the aneurysm.





**Figure 3.** Final intraoperative angiogram showing the completely excluded aneurysm using the GORE EXCLUDER Iliac Branch Device without any endoleak.

## DEVICE

The GORE EXCLUDER Iliac Branch Endoprosthesis has been available in Europe since November 2013, and is specifically designed to treat common iliac aneurysms and aortoiliac aneurysms while preserving flow in the hypogastric artery. This complete system is compatible with a 16-F introducer sheath and offers repositionability

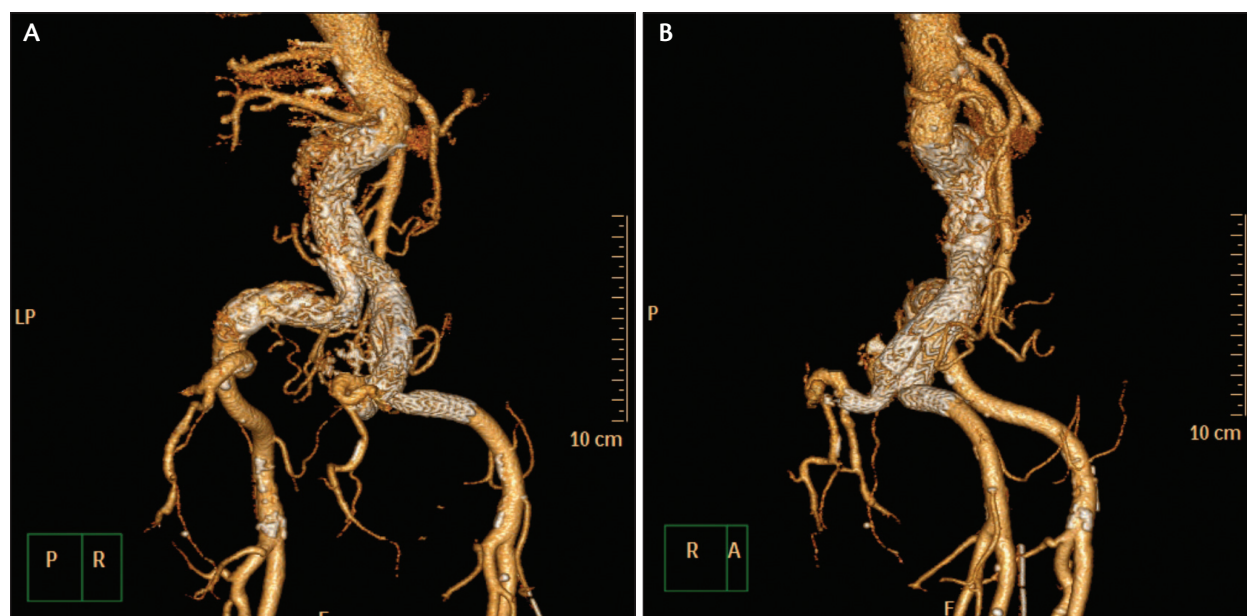
using a simple, two-stage deployment mechanism via a nested deployment knob. Based on the GORE EXCLUDER Device platform, the GORE EXCLUDER Iliac Branch Endoprosthesis is flexible and low profile and is intended to achieve high conformability and sealing in the often considerably tortuous iliac arteries (Figures 4A and 4B).

Required anatomical characteristics include a proximal diameter of the common iliac artery of at least 17 mm. There is no limitation regarding the length of the iliac common artery; the prosthesis can be deployed above the aortic bifurcation. It is recommended, however, that the distance between the renal artery and iliac bifurcation should be at least 16.5 cm.

## DISCUSSION

Common iliac artery aneurysmal changes complicate standard EVAR. The hypogastric artery is at risk of occlusion in 20% to 40% of patients with abdominal aortic aneurysms.<sup>7,8,9</sup>

Occlusions of the internal iliac artery are associated with several potential complications. Regarding the morbidity that is associated with these complications, from today's perspective and technical feasibility, iliac branch technology for hypogastric preservation is a promising option for patients with appropriate anatomy. The GORE EXCLUDER Iliac Branch Endoprosthesis technology has the potential for an effective and safe treatment of most of the iliac artery aneurysms. In the short-term follow-up from our center's experience, the exclusion of the aneurysm, as well as prevention of ischemic complications, was effectively achieved. ■



**Figure 4.** Considerably tortuous aortoiliac arteries demonstrate the flexibility of the GORE EXCLUDER Iliac Branch Endoprosthesis (A and B).

## RESULTS

*In November 2013, we performed the first implantation in Germany in our institution. Our initial experience with the GORE EXCLUDER Iliac Branch Endoprosthesis is based on 15 implantations that we have performed in the last 12 months.*

- Aortoiliac aneurysms: n = 12
- Isolated iliac aneurysms: n = 3
- Mean age: 79 years
- Gender: five male, 10 female
- Mean follow-up (clinical visit, duplex ultrasound, postprocedural computed tomography angiography): 5 months
- Technical success rate: 93% (14/15 implantations)\*
- Complications: no type IA or IA endoleak; four type II endoleaks, no reinterventions, no buttock claudication, and no iliac occlusion
- All iliac components are patent

*\* Due to severe calcification and challenging anatomy of the aortoiliac bifurcation that was underestimated in the case planning.*

*Reza Ghotbi, MD, is with the Department of Vascular and Endovascular Surgery, Helios Hospital Munich-West, Teaching Hospital of Ludwig-Maximilian University of Munich, in Munich, Germany. He has disclosed that he has no financial interests related to this article. Dr. Ghotbi may be reached at reza.ghotbi@helios-kliniken.de.*

*Sylvia Schoenhofer, MD, is with the Department of Vascular and Endovascular Surgery, Helios Hospital Munich-West, Teaching Hospital of Ludwig-Maximilian University of Munich, in Munich, Germany. He has disclosed that he has no financial interests related to this article.*

1. Armon MP, Wenham PW, Whitaker SC, et al. Common iliac artery aneurysms in patients with abdominal aortic aneurysms. *Eur J Vasc Endovasc Surg.* 1998;15:255-257.
2. Hobo R, Sybrandt JE, Harris PL, Buth J; EUROSTAR Collaborators. Endovascular repair of abdominal aortic aneurysms with concomitant common iliac artery aneurysm: outcome analysis of the EUROSTAR Experience. *J Endovasc Ther.* 2008;15:12-22.
3. Henretta JP, Karch LA, Hodgson KJ, et al. Special iliac artery considerations during aneurysm endografting. *Am J Surg.* 1999;178:212-218.
4. Paty PK, Shah DM, Chang BB, et al. Pelvic ischemia following aortoiliac reconstruction. *Ann Vasc Surg.* 1994;8:204-206.
5. Farahmand P, Becquemin JP, Desgranges P, et al. Is hypogastric artery embolization during endovascular aortoiliac aneurysm repair innocuous and useful? *Eur J Vasc Endovasc Surg.* 2008;35:429-435.
6. Karthikesalingam A, Hinchliffe RJ, Holt PJ, et al. Endovascular aneurysm repair with preservation of the internal iliac artery using the iliac branch graft device. *Eur J Vasc Endovasc Surg.* 2010;39:285-294.
7. Wyers MC, Schermerhorn ML, Fillinger MF, et al. Internal iliac occlusion without coil embolization during endovascular abdominal aortic aneurysm repair. *J Vasc Surg.* 2002;36:1138-1145.
8. Bergamini TM, Rachel ES, Kinney EV, et al. External iliac artery-to-internal iliac artery endograft: a novel approach to preserve pelvic inflow in aortoiliac stent grafting. *J Vasc Surg.* 2002;35:120-124.
9. Carpenter JP, Baum RA, Barker CF, et al. Impact of exclusion criteria on patient selection for endovascular abdominal aortic aneurysm repair. *J Vasc Surg.* 2001;34:1050-1054.

## GORE® EXCLUDER® AAA Endoprosthesis

**INDICATIONS FOR USE: Trunk-Ipsilateral Leg Endoprosthesis and Contralateral Leg Endoprosthesis Components.** The GORE® EXCLUDER® AAA Endoprosthesis is intended to exclude the aneurysm from the blood circulation in patients diagnosed with infrarenal abdominal aortic aneurysm (AAA) disease and who have appropriate anatomy as described below: Adequate iliac / femoral access; Infrarenal aortic neck treatment diameter range of 19–32 mm and a minimum aortic neck length of 15 mm; Proximal aortic neck angulation  $\leq 60^\circ$ ; Iliac artery treatment diameter range of 8–25 mm and iliac distal vessel seal zone length of at least 10 mm. **Aortic Extender Endoprosthesis and Iliac Extender Endoprosthesis Components.** The Aortic and Iliac Extender Endoprostheses are intended to be used after deployment of the GORE® EXCLUDER® AAA Endoprosthesis. These extensions are intended to be used when additional length and / or sealing for aneurysmal exclusion is desired. **CONTRAINDICATIONS:** The GORE® EXCLUDER® AAA Endoprosthesis is contraindicated in patients with known sensitivities or allergies to the device materials and patients with a systemic infection who may be at increased risk of endovascular graft infection. Refer to *Instructions for Use* at [goremedical.com](http://goremedical.com) for a complete description of all warnings, precautions, and adverse events.  $R_x$  Only

## GORE® EXCLUDER® Iliac Branch Endoprosthesis

**INDICATIONS FOR USE UNDER CE MARK:** Iliac Branch and Internal Iliac Components. The GORE® EXCLUDER® Iliac Branch Endoprosthesis (IBE) is intended to isolate the common iliac artery from systemic blood flow and preserve blood flow in the external iliac and internal iliac arteries in patients with a common iliac or aortoiliac aneurysm, who have appropriate anatomy, including: Adequate iliac / femoral access; Minimum common iliac diameter of 17 mm at the proximal implantation zone of the IBE; External Iliac artery treatment diameter range of 6.5 – 25 mm and seal zone length of at least 10 mm; Internal iliac artery treatment diameter range of 6.5 – 13.5 mm and seal zone length of at least 10 mm. Trunk-Ipsilateral Leg and Contralateral Leg Endoprosthesis Components. The Trunk-Ipsilateral Leg and Contralateral Leg Endoprostheses are intended to provide proximal seal and fixation to the GORE® EXCLUDER® Iliac Branch Endoprosthesis following deployment of the GORE® EXCLUDER® Iliac Branch Endoprosthesis. For more information on the Trunk-Ipsilateral Leg and Contralateral Leg Endoprosthesis Component indications for use and deployment, see the GORE® EXCLUDER® AAA Endoprosthesis Instructions For Use. Aortic Extender Endoprosthesis and Iliac Extender Endoprosthesis Components. The Aortic and Iliac Extender Endoprostheses can be used after deployment of the GORE® EXCLUDER® Iliac Branch and AAA Endoprostheses. These extensions are used when additional length and / or sealing for aneurysmal exclusion is desired. For more information on Aortic Extender and Iliac Extender indications for use and deployment, see the GORE® EXCLUDER® AAA Endoprosthesis Instructions For Use. **CONTRAINDICATIONS:** The GORE® EXCLUDER® Iliac Branch Endoprosthesis is contraindicated in: Patients with known sensitivities or allergies to the device materials, and patients with a systemic infection who may be at increased risk of endovascular graft infection. Refer to *Instructions for Use* at [goremedical.com](http://goremedical.com) for a complete description of all warnings, precautions, and adverse events.  $R_x$  Only

## Conformable GORE® TAG® Thoracic Endoprosthesis

**INDICATIONS FOR USE IN THE US:** The GORE® TAG® Thoracic Endoprosthesis is intended for endovascular repair of all lesions of the descending thoracic aorta, including: Isolated lesions in patients who have appropriate anatomy, including: adequate iliac / femoral access, aortic inner diameter in the range of 16–42 mm,  $\geq 20$  mm non-aneurysmal aorta proximal and distal to the lesion; Type B dissections in patients who have appropriate anatomy, including: adequate iliac / femoral access,  $\geq 20$  mm landing zone proximal to the primary entry tear; proximal extent of the landing zone must not be dissected, diameter at proximal extent of proximal landing zone in the range of 16–42 mm. **CONTRAINDICATIONS:** Patients with known sensitivities or allergies to the device materials; patients who have a condition that threatens to infect the graft. Refer to *Instructions for Use* at [goremedical.com](http://goremedical.com) for a complete description of all warnings, precautions, and adverse events.  $R_x$  Only

**INDICATIONS FOR USE UNDER CE MARK:** The GORE® TAG® Thoracic Endoprosthesis is indicated for endovascular repair of the descending thoracic aorta. **CONTRAINDICATIONS:** Patients with known sensitivities or allergies to the device materials; patients with a systemic infection who may be at increased risk of endovascular graft infection. Refer to *Instructions for Use* at [goremedical.com](http://goremedical.com) for a complete description of all warnings, precautions, and adverse events.  $R_x$  Only

# WE'VE BEEN KEEPING

[ *A Low Profile* ]

*Now it's time to show you the future of aortic stent-graft technology.*

Low Profile  
Technology

Conformability

Controlled  
Deployment

Branched  
Technology

Leveraging internal core technology from every industry we touch, our distinct capabilities drive performance in aortic endovascular repair.

See how we are changing the future of aortic stent-grafts at:  
**[goremedical.com/aortic/innovation](http://goremedical.com/aortic/innovation)**

Please see accompanying prescribing information in this journal.

GORE®, PERFORMANCE BY DESIGN, and designs are trademarks of W. L. Gore & Associates.  
© 2014, 2015 W. L. Gore & Associates, Inc. AT0965-EN2 MARCH 2015



PERFORMANCE  
by design

AU0931-EN1