




**GORE® VIABAHN®**

Endoprosthesis  
with PROPATEN Bioactive Surface\*

# OPEN MORE POSSIBILITIES



\*As used by Gore, PROPATEN Bioactive Surface refers to Gore's proprietary CBAS Heparin Surface

***Together, improving life***

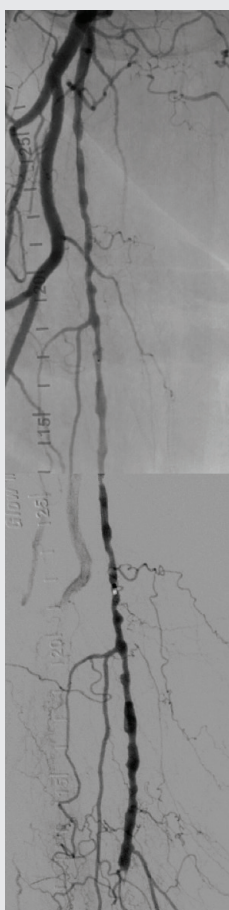
# Superficial femoral artery (SFA)

Strong clinical performance in the most challenging cases including long SFA lesions and chronic total occlusions (CTOs).


High primary patency even in the most challenging disease

Proven patency for complex SFA lesions across seven multicenter, prospective, randomized or single arm studies<sup>1-7</sup>

Long lesion of the right SFA



Before: Proximal SFA disease and mid-SFA occlusion.



After: Post-placement of three 5 mm VIABAHN® Devices.

1089

Lesions studied

71%

CTOs

23 cm

Average lesion length\*

80%

Average primary patency†

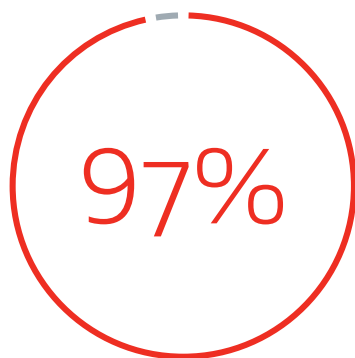
Images courtesy of James Persky, M.D. Used with permission.

\* Weighted average lesion length.

† One-year weighted average primary patency.

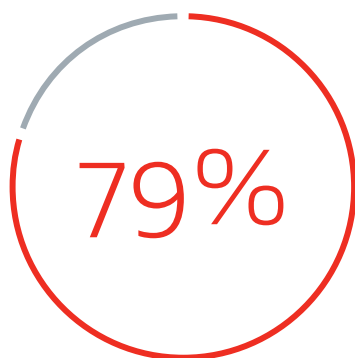
## Durable clinical study outcomes in complex cases:

Comparable clinical results to above the knee surgical bypass (both prosthetic<sup>8</sup> and native vein<sup>4</sup>).



3-year secondary patency  
in complex disease

(27 cm average lesion length, 93% CTOs)<sup>9</sup>



5-year freedom from target  
lesion revascularization (fTLR)<sup>10</sup>

## Recommendations for optimal outcomes in the SFA

### Device sizing considerations

- Treat all of the disease (stent “normal to normal”)<sup>9</sup>
- Overlap devices by at least 1 cm<sup>9</sup>
- Avoid excessive oversizing (> 20%)<sup>9</sup>

### Implantation considerations

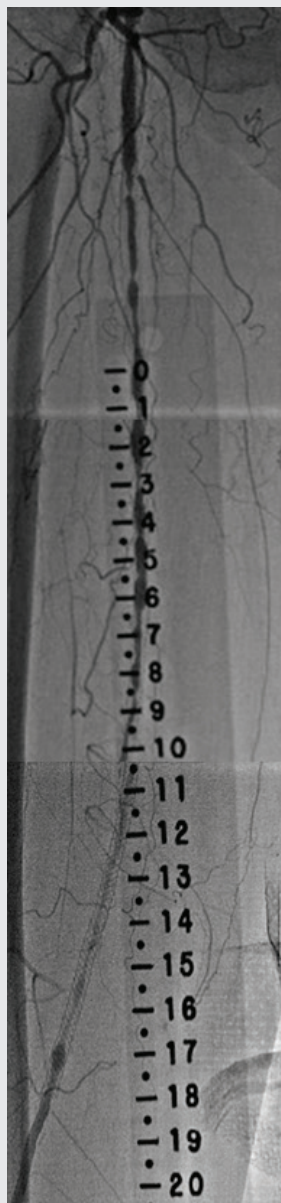
- Ensure adequate inflow and outflow<sup>9</sup>
- Post dilate<sup>9</sup>
- Do not use percutaneous transluminal angioplasty (PTA) outside of the device<sup>9</sup>
- Place device at the SFA origin if proximal SFA disease is present<sup>9</sup>

### Follow-up considerations

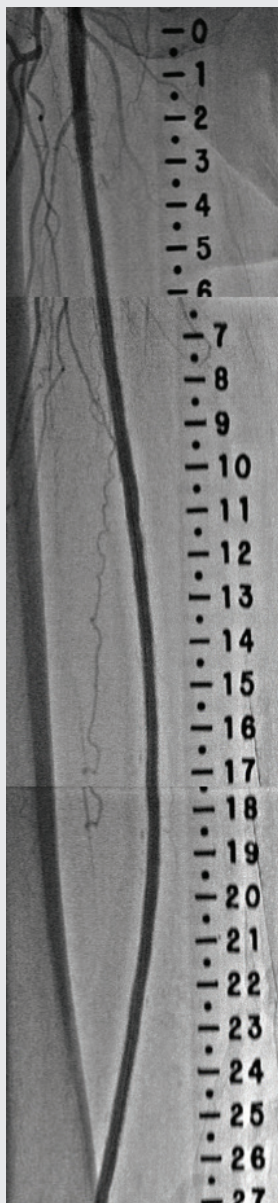
- Regular duplex ultrasonography follow-up<sup>11</sup>
- Prescribe appropriate antiplatelet therapy<sup>9</sup>
- Treat progressing disease<sup>11</sup>

# In-stent restenosis (ISR) of the SFA

Durable treatment for complex in-stent restenotic lesions.



Before: Diffuse SFA ISR in long-stented segment in the SFA.



After: Completion angiogram after placement of VIABAHN® Devices for ISR in the SFA.

## High primary patency even in the most challenging disease:

75% one-year primary with an average lesion length of over 17 cm.<sup>12</sup>

Fewer than one third the number of patients required an intervention at one year compared to PTA.<sup>9</sup>

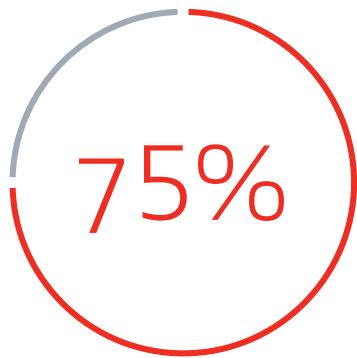
## Durable clinical study outcomes in complex cases:

Four times greater primary patency compared to PTA at two years.<sup>13</sup>

More than three times greater FTLR compared to PTA at two years.<sup>9</sup>

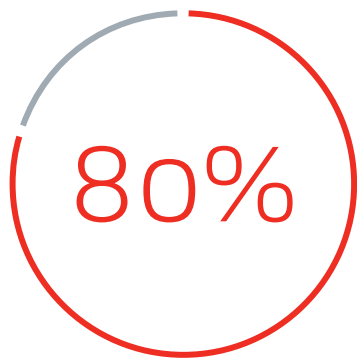
## Proven to reduce reinterventions:

Fewer patients had reintervention procedures compared to PTA at two years.<sup>9</sup>



primary patency at one year<sup>12</sup>

17.3 cm mean lesion length<sup>12</sup>



fTLR at one year<sup>12</sup>

### Recommendations for optimal outcomes in ISR

- Extend the device at least 1 cm proximally and distally from the previously placed stent<sup>9</sup>
- Cover any adjacent disease at least 1 cm beyond the proximal and distal margins of the lesion<sup>9</sup>
- Follow the *Instructions for Use* (IFU) recommendation for 5–20% oversizing using the healthy vessel diameter immediately proximal and distal to the lesion<sup>9</sup>
- Ensure guidewire has traversed the lesion intraluminally before completing PTA<sup>9</sup>

# Iliac artery

The VIABAHN® Device is the only self-expanding stent graft indicated to treat iliac lesions.

---

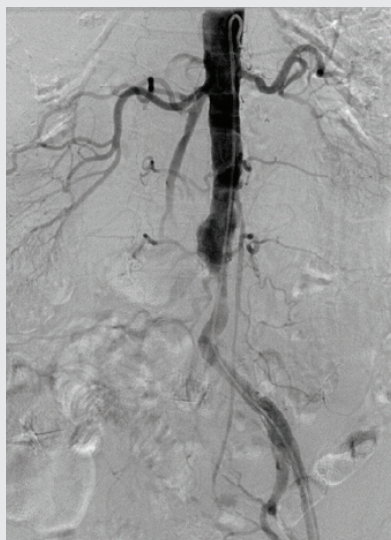High primary patency even in the most challenging disease: Demonstrated 91% one-year primary patency.<sup>14</sup>

---

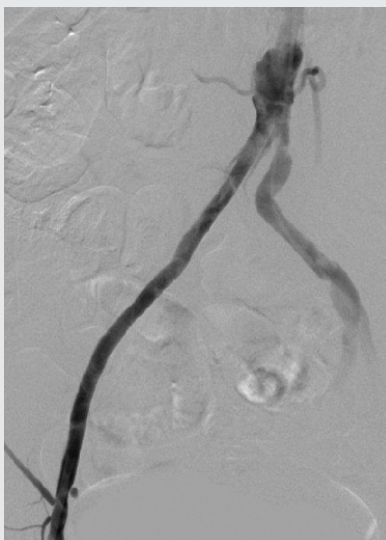## Durable clinical study outcomes in complex cases:

Stent grafts have demonstrated superiority over bare metal stents (BMS) for treating complex iliac lesions.<sup>15,16</sup>

Self-expanding stent grafts, at three years, have demonstrated improved patency over BMS when treating TASC D iliac lesions.<sup>16</sup>



Before: Flush ostial CTO of the right common iliac artery with reconstitution of the proximal common femoral artery.



After: Post-placement of 7 mm x 150 mm VIABAHN® Device and 7 mm x 59 mm balloon expandable covered stent.

## Recommendations for optimal outcomes in the iliac artery

### Device sizing considerations

- Treat all of the disease (stent “normal to normal”)<sup>9</sup>
- Overlap devices by at least 1 cm<sup>9</sup>
- Avoid excessive oversizing (> 20%)<sup>9</sup>

### Implantation considerations

- Ensure adequate inflow and outflow<sup>9</sup>
- Post dilate<sup>9</sup>
- Do not use PTA outside of the device<sup>9</sup>

### Follow-up considerations

- Prescribe appropriate antiplatelet therapy<sup>9</sup>
- Treat progressing disease<sup>11</sup>

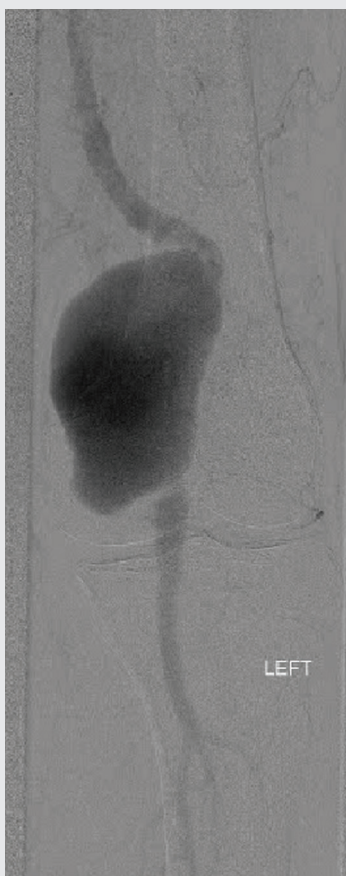


# Popliteal artery aneurysm (PAA)

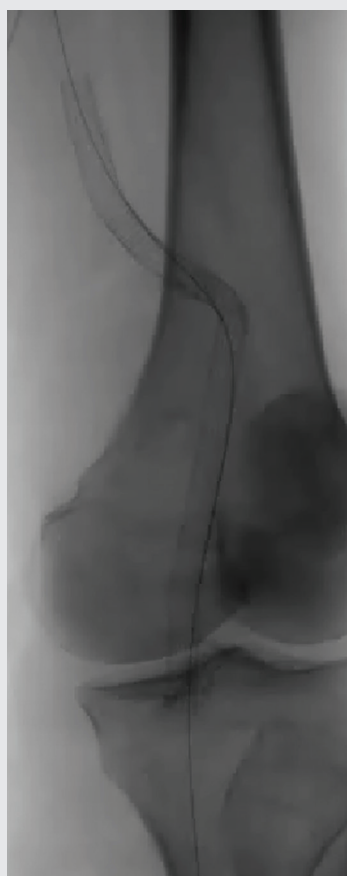
Strong clinical performance in challenging PAA cases.

Endovascular repair of popliteal aneurysms is associated with acceptable long-term patency and a very low risk of limb loss<sup>17</sup>

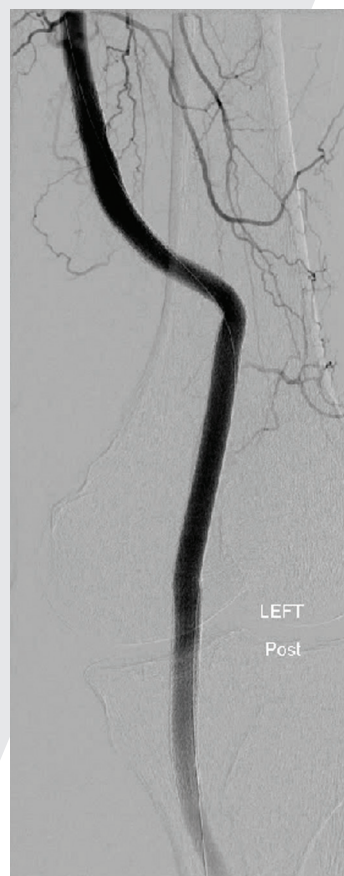- Patency rates at two to six years in PAA (70–86%) are comparable to those reported for surgical bypass at five years (69–88%)<sup>18–23</sup>



Before: Large (5 cm diameter) left popliteal artery aneurysm.



After: VIABAHN® Device placement to exclude the aneurysm.

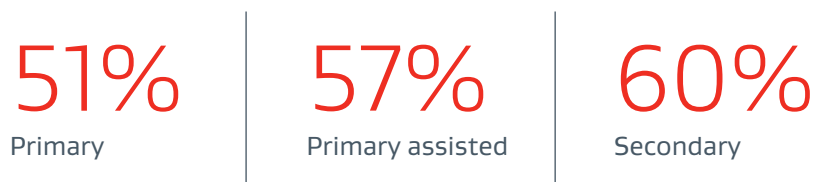


After: Completion angiography showing good conformability to the artery tortuosity and total exclusion of the aneurysm by the VIABAHN® Device.



## VIABAHN® Device 10-year patency rates in PAA<sup>17</sup>

---



## Recommendations for optimal outcomes in the PAAs

### Device sizing considerations

- Pre-procedure planning with adequate imaging: image-centered, magnified-view contrast angiography, including a marker guidewire or catheter.<sup>9</sup>
- Select appropriate device length. Experience has shown that devices can shorten by 10% as they are deployed within the aneurysm.<sup>24</sup>
- Select device diameter according to IFU.<sup>9</sup>
- Overlap multiple devices by at least 2 cm. Overlapping devices should not differ by more than 1 mm in diameter, with one exception: if 13 mm and 11 mm devices are overlapped, the 11 mm device should be placed first and the 13 mm should be placed inside of the 11 mm device.<sup>9</sup>
- Avoid overlapping multiple devices in the hinge point zone of the popliteal artery.<sup>25, 26</sup>
- Select at least 2 cm of non-aneurysmal artery (proximal and distal) to serve as landing zones.<sup>9</sup>

### Implantation considerations

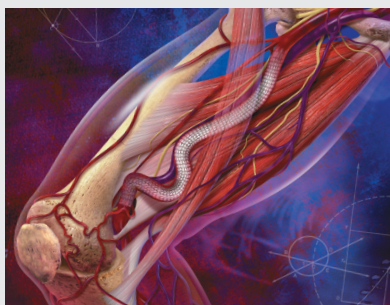
- Use a stiff guidewire.<sup>9</sup>
- Deploy the VIABAHN® Device slowly.<sup>9</sup>
- Do not use VIABAHN® Device for treatment of lesions that would not allow an operative salvage bypass procedure.<sup>9</sup>

### Follow-up considerations

- Prescribe appropriate antiplatelet therapy.<sup>9</sup>
- Flexion (bent-knee) arteriography post-implantation may be performed at the physician's discretion to verify adequate device placement is maintained.<sup>27</sup>

# Features and benefits

The unique design of the VIABAHN® Device enables treatment of even the most challenging peripheral cases.



## Performs as an endoluminal bypass:

Covers and excludes diseased and irregular tissue.

Provides a barrier from tissue ingrowth, minimizing ISR.



## Conformable yet durable design:

Like with all Gore single nitinol wire stents, the design and frame construction reduces strain to provide mechanical durability.

Proven flexibility maintains flow at points of flexion and increases anatomical options.



## Ease of use:

Robust configurations cover a broad range of patient needs.

Radiopaque markers enhance endoprosthesis visibility.

Low profile delivery system makes it potentially easier to reach and treat challenging lesions.

## Lasting thromboresistance:

CBAS Heparin Surface, also featured in the GORE® PROPATEN® Vascular Graft, is the proven lasting heparin bonding technology designed to resist thrombus formation.<sup>28</sup>

### **GORE® VIABAHN® Endoprosthesis with PROPATEN Bioactive Surface**

The bioactive luminal surface of a 5 mm diameter GORE® VIABAHN® Endoprosthesis with PROPATEN Bioactive Surface appears free of thrombus after two hours in an in vitro blood loop model.

### **Control endoprosthesis**

The non-bioactive luminal surface of a control endoprosthesis (5 mm diameter) appears covered with thrombus after 90 minutes in the same blood loop model (Data on file; W. L. Gore & Associates, Inc; Flagstaff, AZ).



---

**The VIABAHN® Device has a reported fracture rate of < .015% across all uses.**

(Data on file 2020; W. L. Gore & Associates, Inc.; Flagstaff, AZ.)

---

# Sizing tables

## GORE® VIABAHN® Endoprosthesis with PROPATEN Bioactive Surface

### .035" guidewire compatibility

Device sizing		Introducer sheath (Fr)					
Endoprosthesis labeled diameter* (mm)	Recommended vessel diameter† (mm)	2.5 cm device length*	5 cm device length*	10 cm device length*	15 cm device length*	25 cm device length*	Recommended balloon diameter for device touch-up‡ (mm)
9	7.6–8.5	–	8	8	8	–	9
10	8.6–9.5	–	8	8	8	–	10
11	9.6–10.5	–	10	10	–	–	12
13	10.6–12.0	–	10‡	10‡	–	–	14

### .014" or .018" guidewire compatibility

Device sizing		Introducer sheath (Fr)					
Endoprosthesis labeled diameter* (mm)	Recommended vessel diameter† (mm)	2.5 cm device length*	5 cm device length*	10 cm device length*	15 cm device length*	25 cm device length*	Recommended balloon diameter for device touch-up (mm)
5	4.0–4.7	6	6	6	6	6	5
6	4.8–5.5	6	6	6	6	6	6
7	5.6–6.5	7	7	7	7	7	7
8	6.6–7.5	7	7	7	7	7§	8

\* Labeled device diameters and lengths are nominal.

† Recommended endoprosthesis compression within the vessel is approximately 5–20%.

‡ The 13 mm diameter device is not compatible with the 10 Fr COOK FLEXOR CHECK-FLO Introducer.

§ The 8 mm x 25 cm device is not compatible with the 7 Fr COOK CHECK-FLO Introducer.

|| For the 11 and 13 mm diameter devices, balloon inflation pressure should not exceed 8 atm.

COOK, CHECK-FLO and FLEXOR are trademarks of Cook Medical, Inc.

## References

- Ohki T, Kichikawa K, Yokoi H, *et al.* Long-term results of the Japanese multicenter Viabahn trial of heparin bonded endovascular stent grafts for long and complex lesions in the superficial femoral artery. *Journal of Vascular Surgery* 2021;74(6):1958-1967.e2.
- Lammer J, Zeller T, Hausegger KA, *et al.* Sustained benefit at 2 years for covered stents versus bare-metal stents in long SFA lesions: the VIASTAR Trial. *Cardiovascular & Interventional Radiology* 2015;38(1):25-32.
- Zeller T, Peeters P, Bosiers M, *et al.* Heparin-bonded stent-graft for the treatment of TASC II C and D femoropopliteal lesions: the Viabahn-25 cm Trial. *Journal of Endovascular Therapy* 2014;21(6):765-774.
- Reijnen MMPJ, van Walraven LA, Fritschy WM, *et al.* 1-year results of a multicenter randomized controlled trial comparing heparin-bonded endoluminal to femoropopliteal bypass. *JACC: Cardiovascular Interventions* 2017;10(22):2320-2331.
- Saxon RR, Chervu A, Jones PA, *et al.* Heparin bonded, expanded polytetrafluoroethylene lined stent graft in the treatment of femoropopliteal artery disease: 1 year results of the VIPER (Viabahn Endoprosthesis with Heparin Bioactive Surface in the Treatment of Superficial Femoral Artery Obstructive Disease) Trial. *Journal of Vascular & Interventional Radiology* 2013;24(2):165-173.
- Iida O. Twelve-month outcomes from the Japanese post-market surveillance study of the GORE® VIABAHN® Endoprosthesis as treatment for symptomatic peripheral arterial disease in the superficial femoral arteries. Presented at LEIPZIG Interventional Course (LINC)2021; January 25-29, 2021; Leipzig, Germany.
- Iida O, Takahara M, Soga Y, *et al.*; VANQUISH Investigators. One-year outcomes of heparin-bonded stent-graft therapy for real-world femoropopliteal lesions and the association of patency with the prothrombotic state based on the prospective, observational, multicenter Viabahn Stent-Graft Placement for Femoropopliteal Diseases Requiring Endovascular Therapy (VANQUISH) Study. *Journal of Endovascular Therapy* 2021;28(1):123-131.
- McQuade K, Gable D, Pearl G, Theune B, Black S. Four-year randomized prospective comparison of percutaneous ePTFE/nitinol self-expanding stent graft versus prosthetic femoral-popliteal bypass in the treatment of superficial femoral artery occlusive disease. *Journal of Vascular Surgery* 2010;52(3):584-591.
- GORE® VIABAHN® Endoprosthesis with PROPATEN Bioactive Surface Instructions for Use (IFU). W. L. Gore & Associates, Inc website. Accessed February 3, 2021. <https://eifu.goremedical.com/>
- Iida O. Update on value and indications of the Viabahn self-expanding stent-graft for fempop occlusive disease: evolution of the device: technical tips and 5-year results from Japan. Presented at the 46th Annual Symposium on Vascular and Endovascular Issues, Techniques, Horizons (VEITHSymposium); November 19 -23, 2019; New York, NY.
- Troutman DA, Madden NJ, Dougherty MJ, Calligaro KD. Duplex ultrasound diagnosis of failing stent grafts placed for occlusive disease. *Journal of Vascular Surgery* 2014;60(6):1580-1584.
- Bosiers M, Deloose K, Callaert J, *et al.* Superiority of stent-grafts for in-stent restenosis in the superficial femoral artery: twelve-month results from a multicenter randomized trial. *Journal of Endovascular Therapy* 2015;22(1):1-10.
- Bosiers M, Deloose K. 2-year results of the RELINE Trial comparing Viabahn Stent-Grafts to POBA for ISR show durable benefits to endograft treatment. Presented at the 41st Annual Symposium on Vascular and Endovascular Issues, Techniques, Horizons (VEITHSymposium); November 18-22, 2014; New York, NY. Abstract 168.
- Lammer J, Dake MD, Bley J, *et al.* Peripheral arterial obstruction: prospective study of treatment with a transluminally placed self-expanding stent graft. *Radiology* 2000;217(1):95-104.
- Chang RW, Goodney PP, Baek JH, Nolan BW, Rzucidlo EM, Powell RJ. Long-term results of combined common femoral endarterectomy and iliac stenting/stent grafting for occlusive disease. *Journal of Vascular Surgery* 2008;48(2):362-367.
- Piazza M, Squizzato F, Dall'Antonia A, *et al.* Outcomes of self expanding PTFE covered stent versus bare metal stent for chronic iliac artery occlusion in matched cohorts using propensity score modelling. *European Journal of Vascular & Endovascular Surgery* 2017;54(2):177-185.
- Golcwehr B, Zeebregts CJ, Reijnen MMPJ, Tielliu IFJ. Long-term outcome of endovascular popliteal artery aneurysm repair. *Journal of Vascular Surgery*. 2018; 67(6): 1797-1804.
- Antonello M, Frigatti P, Battocchio P, *et al.* Endovascular treatment of asymptomatic popliteal aneurysm: 8-year concurrent comparison with open repair. *Journal of Cardiovascular Surgery* 2007;48(3):267-274.
- Curi MA, Geraghty PJ, Merino OA, *et al.* Mid-term outcomes of endovascular popliteal artery aneurysm repair. *Journal of Vascular Surgery* 2007;45(3):505-510.
- Ghotbi R, Sotiriou A, Schönhofer S, Zikos D, Schips K, Westermeier W. Stent-graft placement in popliteal artery aneurysms: midterm results. *Vascular Disease Management* 2007;4(4):123-127.
- Rajasinghe HA, Tzilinis A, Keller T, Schafer J, Urrea S. Endovascular exclusion of popliteal artery aneurysms with expanded polytetrafluoroethylene stent-grafts: early results. *Vascular & Endovascular Surgery* 2007;40(6):460-466.
- Tielliu IFJ, Verhoeven ELG, Zeebregts CJ, Prins PR, Bos WTGJ, van den Dungen JJAM. Endovascular treatment of popliteal artery aneurysms: is the technique a valid alternative to open surgery? *Journal of Cardiovascular Surgery* 2007;48(3):275-279.
- Wain RA, Hines G. A contemporary review of popliteal artery aneurysms. *Cardiology in Review* 2007;15(2):102-107.
- Ghotbi R, Sotiriou A, Schönhofer S, Zikos D, Schips K, Westermeier W. Stent-graft placement in popliteal artery aneurysms: midterm results. *Vascular Disease Management* 2007;4(4):123-127.
- P. J. Geraghty PJ. Endovascular treatment of lower extremity aneurysms. *Seminars in Vascular Surgery* 2008; 21: 195-199.
- Tielliu IFJ, Verhoeven ELG, Zeebregts CJ, Prins TR, Span MM, van den Dungen JJAM. Endovascular treatment of popliteal artery aneurysms: results of a prospective cohort study. *Journal of Vascular Surgery* 2005;41(4):561-566.
- F. J. Tielliu, C. J. Zeebregts, G. Vourliotakis, F. Bekkema, J. J. A. M. Van den Dungen, T. R. Prins, E. L. G. Verhoeven, Stent Fractures in Hemobahn/ Viabahn Stent Graft after Endovascular Popliteal Aneurysm Repair. *Journal of Vascular Surgery* 2010;51(6): 1413-1418.
- CBAS Heparin Surface. W. L. Gore & Associates website. Accessed January 20, 2021. <https://www.goremedical.com/cbas/references>

## Notes

[illegible]



[illegible]

 Consult Instructions  
for Use  
[eifu.goremedical.com](http://eifu.goremedical.com)

Refer to *Instructions for Use* at [eifu.goremedical.com](http://eifu.goremedical.com) for a complete description of all applicable indications, warnings, precautions and contraindications for the markets where this product is available. <sup>Rx</sup> Only

Products listed may not be available in all markets.

COOK, CHECK-FLO and FLEXOR are trademarks of Cook Medical, Inc.

CBAS is a trademark of Carmeda AB, a wholly owned subsidiary of W. L. Gore & Associates, Inc.

GORE, *Together, improving life*, HEMOBAHN, PROPATEN, VIABAHN and designs are trademarks of W. L. Gore & Associates.

© 2021, 2022 W. L. Gore & Associates, Inc. 22515555-EN MARCH 2022

---

**W. L. Gore & Associates, Inc.**  
[goremedical.com](http://goremedical.com)

**Asia Pacific** +65 6733 2882 **Australia / New Zealand** 1800 680 424 **Europe** 00800 6334 4673  
**United States** Flagstaff, AZ 86004 800 437 8181 928 779 2771

