

Supplement to

Sponsored by Gore & Associates

Endovascular TODAY

August 2017



PRESERVING THE
**HYPOGASTRIC
ARTERY**

Techniques of Endovascular Aortoiliac Repair Using an Iliac Branch Endoprosthesis

BY GUSTAVO S. ODERICH, MD; GIULIANO DE ALMEIDA SANDRI, MD;
AND EMANUEL TENORIO, MD, PhD

Endovascular aneurysm repair (EVAR) has revolutionized treatment of abdominal aortic aneurysms. However, the applicability of EVAR continues to be challenged in patients with unfavorable anatomy because of inadequate proximal or distal landing zones or involvement of the renal, mesenteric, and iliac arteries.¹ In these patients, exclusion of one or both internal iliac arteries and extension of the stent graft to the external iliac artery has been applied frequently to extend the indications of EVAR, accepting the risks of buttock or thigh claudication, erectile dysfunction, ischemic colitis, gluteal or perineal necrosis, spinal cord injury, and acute limb ischemia.

The development of iliac branch devices has allowed incorporation of one or both internal iliac arteries using a total endovascular approach with modular stent grafts.²⁻⁶ There are currently five iliac branch device designs by three manufacturers. The GORE® EXCLUDER® Iliac Branch Endoprosthesis (IBE) is the first and only commercially available iliac branch device in the United States. The early and midterm outcomes have shown excellent technical success and patency rates, without increase in mortality or stent graft–related complications.⁷

ANATOMICAL CONSIDERATIONS

The challenges imposed with placement of a stent in the internal iliac artery are the same for any specific iliac branch device and also for parallel stent grafts. The most common limitation is inadequacy of the internal iliac artery because of aneurysms involving branches without a suitable landing zone. Although this represents a violation of the recommendations for use of these devices, it is not an absolute contraindication. Repair can still be done to one of the internal iliac branches, usually the posterior divisional branch. Another limitation is an excessively short distance between the aortic and iliac bifurcation. Although this limitation may be less important for parallel grafts, it can also be overcome with branch designs. In the IBE pivotal

trial, one-third of the patients had extension of the IBE up and above the aortic bifurcation. A very narrow common iliac artery at the origin of the internal iliac artery may be a relative contraindication with any approach. Finally, severe tortuosity and presence of narrow or excessively diseased iliac arteries pose anatomical challenges for these procedures.

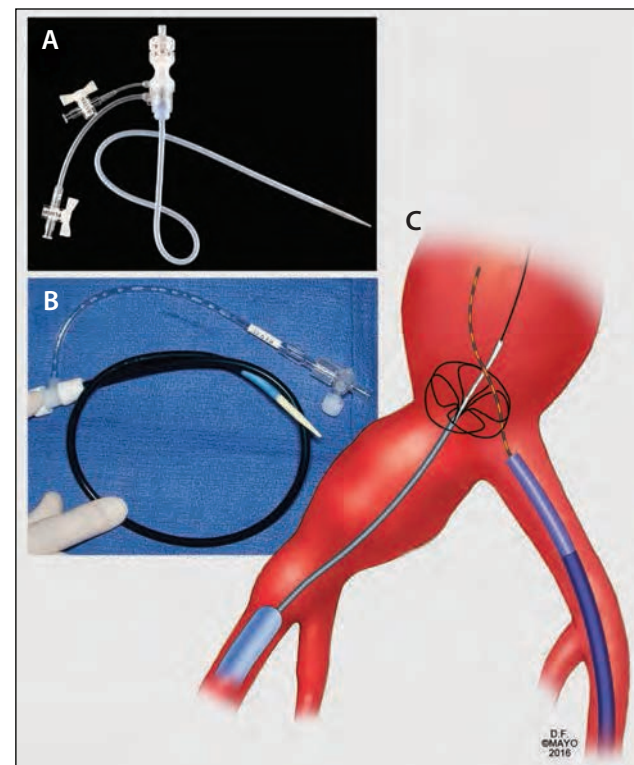


Figure 1. Ancillary tools that are used for iliac branch procedures include use of flexible 12 Fr sheaths such as the GORE® DrySeal Flex Introducer Sheath (A) or the COOK® FLEXOR® Ansel Guiding Sheath (B). Typically, the COOK® INDY OTW Vascular Retriever, which is advanced over the wire, is most useful to snare the 480 cm COOK® METRO® Wire (C). Used with permission of Mayo Foundation for Medical Education. All rights reserved.

The IBE can be used for unilateral or bilateral aortoiliac aneurysms and also for isolated iliac aneurysms. Anatomic criteria and sizing guidelines proposed in the instructions for use (IFU) are summarized as follows:

1. Adequate iliac and femoral access compatible with the 16 Fr introduction system, without excessive tortuosity or calcifications
2. Minimum proximal common iliac artery diameter of 17 mm
3. External iliac artery with diameter range between 6.5 mm and 25 mm and ≥ 30 mm in length (recommended) with a nonaneurysmal seal zone of ≥ 10 mm
4. Internal iliac artery with diameter range between 6.5 mm to 13.5 mm and ≥ 30 mm in length (recommended) with a nonaneurysmal seal zone of ≥ 10 mm

ANCILLARY TOOLS

Techniques of iliac branch device placement require more advanced endovascular skills and a comprehensive inventory with a wide variety of balloons, stents, stent grafts, catheters, guidewires, and sheaths. Although many of the tools are variable depending on physician preference, a few are essential to the success of the technique. Our preference is to use a 45 cm 12 Fr GORE® DrySeal Flex Introducer Sheath

(Figure 1), which has a flexible dilator and was designed especially for the IBE procedure. Although the IFU suggests a 0.035 inch guidewire for through-and-through femoral access, we use the 0.25 inch COOK® TRACER METRO® Wire Guide, which is 480 cm long and has enough length for exchanges while allowing continuous traction from the foot of the table. In addition, the COOK® INDY OTW Vascular Retriever is optimal for advanced aortic procedures.

TECHNIQUE

The procedure is performed in a hybrid room with a fixed imaging unit. Our preference is to use a percutaneous approach, unless the common femoral arteries are calcified or if there is a high bifurcation. After achieving access, the patient is systematically heparinized, and an activated clotting time (ACT) > 225 seconds is maintained throughout the case. Onlay fusion technology is used to locate the ostia of the internal iliac arteries. Most of the guidewire and catheter manipulations are done using a COOK® KUMPE Access Catheter and a floppy 0.035 inch hydrophilic guidewire. A 16 Fr GORE® DrySeal Flex Introducer Sheath is advanced over a COOK® LUNDERQUIST® Wire Guide in the ipsilateral side, and a 12 Fr GORE® DrySeal Flex Introducer Sheath is advanced over a COOK® LUNDERQUIST® Extra Stiff Wire

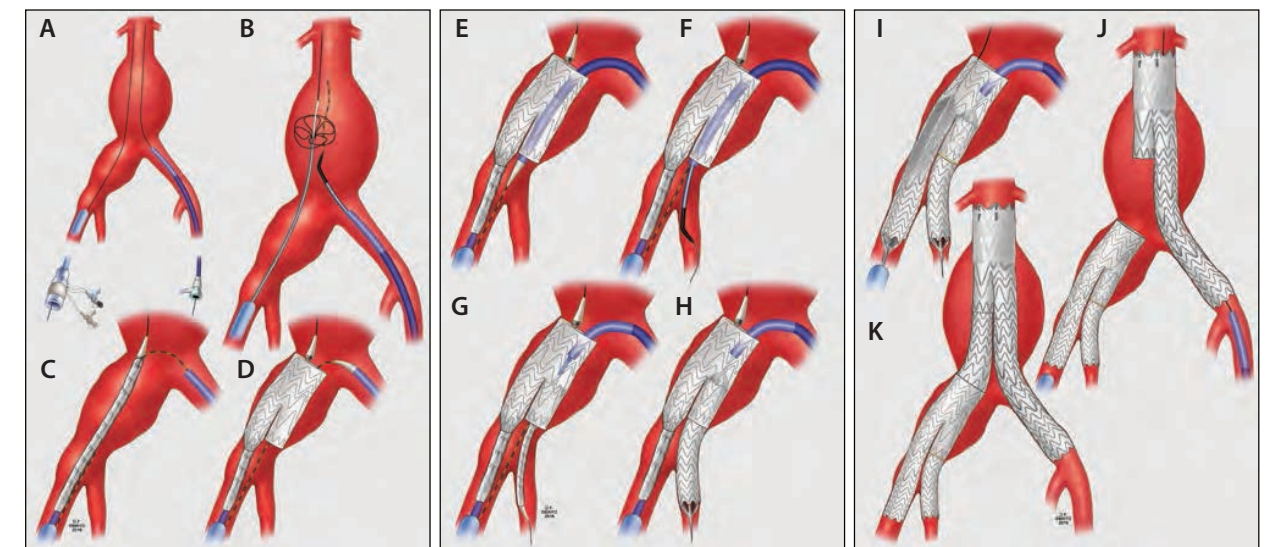


Figure 2. Technique of endovascular repair using the GORE® EXCLUDER® Iliac Branch Endoprosthesis. Bilateral femoral access is established (A), and a guidewire is snared to establish femoral-femoral access (B). The device is loaded into the aortic wire, and the preloaded wire and advanced into position (C). It is important to document that there is no wire wrapping. The device is deployed releasing the iliac branch (D). A 12 Fr sheath is advanced up and over the aortic bifurcation into the iliac branch (E). A buddy catheter is used to selectively catheterize the internal iliac artery (F). The internal iliac component stent is advanced into the internal iliac artery (G) and deployed (H). The stent is ballooned, and the remaining external iliac limb is deployed. The delivery system is removed. Kissing-balloon angioplasty is performed in the transition of the iliac branch (I). The remainder of the repair includes deployment of a GORE® EXCLUDER® Device via the contralateral femoral approach (J), followed by a 23 or 27 mm iliac extension from the contralateral gate to the IBE (K). Used with permission of Mayo Foundation for Medical Education. All rights reserved.

Guide in the contralateral side (Figure 2A and 2B). A buddy catheter is introduced via the 16 Fr sheath, and an Indy snare is introduced in the contralateral 12 Fr sheath. The COOK TRACER METRO Wire Guide is snared, establishing the through-and-through femoral access. The IBE is prepped with normal saline flushes. It has a removable guidewire tube, which is included to allow preloading of the up-and-over through wire. This tube should not be removed at this point. Instead, the through-and-through guidewire is loaded through the green cannula tube, while the IBE is loaded into the COOK LUNDERQUIST Extra Stiff Wire Guidewire. The green cannula is then removed, and the IBE is advanced into position over both wires. Limited contrast angiography can be obtained through the 16 Fr ipsilateral sheath to demonstrate the level of the iliac bifurcation, before IBE deployment.

One of the first and most important steps is to determine that there is no wire wrapping involving the preloaded guidewire and the device cannula. If wire wrapping is noted, the device should be rotated to unwrap the wire. The first step of deployment is done, releasing the iliac branch portal, which should be deployed 1 to 1.5 cm above the iliac bifurcation (Figure 2C and 2D) to aid in internal iliac artery cannulation. The 12 Fr sheath is advanced up and over the aortic bifurcation using a push-and-pull movement. The sheath is positioned at the distal end of the iliac branch portal (Figure 2E). A buddy catheter and guidewire are used to catheterize the internal iliac artery and posterior branch (Figure 2F). While advancing the buddy catheter into the 12 Fr sheath, it is important to place continuous traction in the through-and-through COOK TRACER METRO Wire Guide. This helps prevent wrapping of the catheter and the COOK TRACER METRO Wire Guide, which could create difficulty in advancing the bridging stent. Once the COOK® AMPLATZ Support Wire Guide, extra stiff, is positioned in the posterior divisional branch, we recommend exchanging the guidewire for a 1 cm short-tip COOK® AMPLATZ Fixed Core Wire Guide.

Next, contrast angiography is obtained via sheath injection for measurements and to determine the distal landing zone within the internal iliac artery. The IBE is introduced over the COOK AMPLATZ Support Wire Guide, extra stiff, and deployed into the internal iliac artery (Figure 2G and H). The iliac branch portal is dilated using a 14 mm angioplasty balloon, while the external iliac stent portion of the device is deployed and the delivery catheter is removed. Kissing-balloon angioplasty is performed using a COOK® CODA® Balloon Catheter for the external iliac artery (Figure 2I). Completion angiography of the iliac branch is performed with injection via the 12 Fr sheath, while the 16 Fr sheath is aspirated. The remainder of the procedure is a standard EVAR, with introduction of the GORE® EXCLUDER® Device using the contralateral femoral approach (Figure 2J). The device main body is deployed below the lowest renal artery, while the

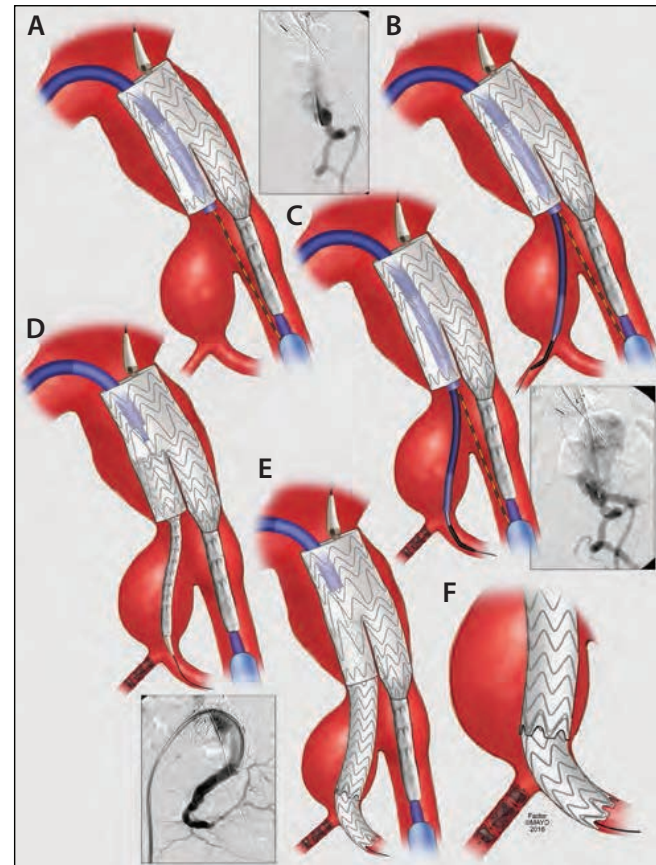


Figure 3. A patient with large internal iliac artery aneurysms needs a modification of the technique. After deployment of the iliac branch device (A), the 12 Fr sheath is advanced, and the anterior division branches are catheterized (B) and excluded using ST. JUDE AMPLATZER® Vascular Plug or coils (C). The posterior division branch is then catheterized. The safest maneuver is to place first the proximal stent into the aneurysm sac (D) and then extend the repair into the posterior branch by placement of an additional component (E, F). Used with permission of Mayo Foundation for Medical Education. All rights reserved.

ipsilateral iliac limb remains constrained. The contralateral gate is cannulated via the side of the IBE. The repair is extended from the contralateral gate to the main body of the IBE using a flared 23 or 27 mm iliac limb extension (Figure 2K). At this point, the ipsilateral limb of the GORE EXCLUDER Device is deployed, and overlaps are dilated with the COOK CODA Balloon Catheter.

BILATERAL ILIAC ANEURYSMS

The indications of iliac branch devices have been expanded to patients with bilateral iliac aneurysms with high rates of technical success and low morbidity and mortality. Special considerations are selection of side for the aortic device, which is usually placed in the straightest side or longer distance between the renal-iliac bifurcation. Upon advancement of

the aortic stent graft delivery system, it is critical to avoid dislodgement of the iliac branch component. This can be done by maintaining the balloon inflated in the iliac branch while the larger sheath is advanced across the first IBE.

INTERNAL ILIAC ANEURYSMS

The presence of aneurysmal internal iliac arteries with inadequate landing zone for placement of the bridging stent represents the main reason for anatomical unsuitability of iliac branch devices according to their IFU. Increasing clinical experience has been reported with extension of the repair to the posterior division branch of the internal iliac artery while using coils or plugs to exclude the anterior branch or other smaller side branches. In these cases, the IBE is deployed using the techniques already described. The internal iliac artery is catheterized, and a 7 or 8 Fr COOK® FLEXOR® Raabe Guiding Sheath is advanced into the aneurysmal iliac artery (Figure 3). The anterior division branch is excluded using ST. JUDE AMPLATZER® Vascular Plug or coils, although plugs are ideal because of the lack of metallic artifact on surveillance CT studies. If the branch is excluded, it is useful to leave the plug connected and to use a buddy catheter to go the next branch or the posterior branch. This maneuver keeps the sheath in close proximity to the next branch, minimizing manipulations.

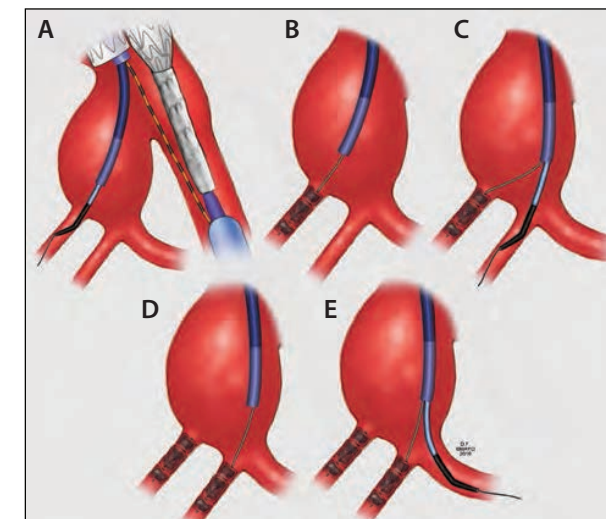


Figure 4. When multiple branches need to be excluded, this is done by selective catheterization of each branch (A) and placement of ST. JUDE AMPLATZER® Vascular Plug or coils (B). It is most useful to keep the plug connected to secure the sheath either with the connecting plug wire or a separate buddy wire, while a catheter is used to catheterize the next adjacent branch (C). This maneuver is repeated (D), and the posterior branch is used as a target for the iliac branch device (E). Used with permission of Mayo Foundation for Medical Education. All rights reserved.

The posterior branch is catheterized, and a COOK AMPLATZ Support Wire Guide, extra stiff, is positioned. The repair is extended into the posterior branch by placing the first branch component into the internal iliac artery using the iliac bridging stent and then to further extend to the divisional branches. Finally, the internal iliac aneurysm may be large and have numerous side branches. It is important to exclude all side branches to avoid retrograde type II endoleak (Figure 4). The technique of going from one side branch to the other using a buddy catheter is very useful to help minimize catheter manipulations.

CONCOMITANT FENESTRATED AND BRANCHED STENT GRAFT REPAIR

Preservation of internal iliac artery perfusion is important to minimize risk of spinal cord injury. Among patients who have extensive aortic coverage during repair of thoracoabdominal aortic aneurysms, occlusion of a collateral network has been associated with higher rates of immediate paraplegia and lack of recovery. Therefore, every attempt should be done to preserve the internal iliac artery using iliac branch devices or alternative techniques. In these cases, it is important to minimize lower extremity ischemia, which can be done by expeditious technique, use of femoral conduits, or preferential use of branches for the visceral arteries, which can be performed via the brachial approach.

COMMON PROBLEMS AND BAILOUT MANEUVERS

Iliac branch devices require familiarity with endovascular techniques and the availability of a comprehensive inventory with wide range of guidewires, balloons, catheters, sheaths, and stents. Some of the most common intraprocedural problems are described here.

Pseudo-occlusion of the Internal Iliac Artery

Patients with exceedingly tortuous and noncalcified iliac arteries may have the uncommon occurrence of a pseudo-obstruction of the origin of the internal iliac artery after placement of a stiff guidewire system. Before introduction of the iliac branch device and its deployment, it is prudent to document patency of the internal iliac artery. If occlusion is documented, the delivery system should be removed and repeat angiography would reveal a widely patent origin of the internal iliac artery. Some of the techniques to solve the problem include placement of a short balloon-expandable stent at the origin of the vessel with careful attention to avoid stenting into the common iliac artery, or a double contralateral puncture to introduce a separate sheath, with stenting only if absolutely needed because of inability to catheterize the vessel via the 12 Fr contralateral sheath.

Difficult catheterization of the internal iliac artery

Catheterization of the internal iliac artery may be difficult or impossible because of misalignment of the branch, presence of a shelf precluding enough space for the delivery system causing occlusion of the origin of the internal iliac artery, or ostial occlusive disease. With deployment of the iliac branch that is not well aligned, the device can be gently rotated so that catheterization is easier. The presence of occlusive ostial disease can be dealt with by preemptive angioplasty. However, the most difficult scenario is when there is not enough space for the delivery system. Current recommendation is a minimum diameter of 14 mm in the iliac bifurcation, but this can be decreased to 12 mm in experienced hands with high technical success.

Kinks

One of the most frequent failure mechanisms are kinks, which can occur in almost any of the joints involving the iliac branch, the bridging stent, or the iliac limb extension. Kinks have occurred less frequently with the IBE compared to historical results of other iliac branch devices. In particular, a kink at the distal external iliac limb stent can result in occlusion of the stent, but this has not been observed with the IBE components in the pivotal trial. Presence of a kink needs to be immediately recognized intraoperatively and treated by placement of an additional stent.*

Branch Occlusion

Branch occlusion is rare intraoperatively and uncommon in the first 30 days. However, early occlusion of an iliac branch is usually technical or patient selection-related and typically has a culprit lesion or cause. Some of the most common causes are kinks in the internal iliac component, placement of long stents into divisional branches, history of prior branch occlusions, disease outflow branches of the internal iliac artery, and vessel dissection with flow compromise. In patients with these complications or predisposing factors, all measures to improve flow should be done, and long-term dual antiplatelet therapy with or without anticoagulation is recommended.

Perforations and Dissections

Branch stenting requires advancement of stiff guidewires and delivery sheaths. Preferentially, the guidewire should be positioned in the larger segment of the posterior division branch, avoiding positioning the tip within a small branch, which is more prone to perforation. In addition, any manipulation should be done with a floppy guidewire with careful attention to avoid inducing a dissection of the branch.

CONCLUSION

Iliac branch technology represents one of the methods by which complex anatomy can be treated with an endovascular approach in a manner analogous to open repair. The principles of antegrade pelvic blood flow are maintained, and patients are encouraged to exercise following their repair. The technique with the IBE has been reproduced with satisfactory results in many centers, achieving high technical success and low morbidity and mortality. The iliac bed is an appealing region to perfect such techniques, as a technical failure in the setting of an iliac aneurysm most frequently results in an occluded internal iliac artery, which is how most aneurysms were managed until recent approval of the GORE® EXCLUDER® Iliac Branch Endoprosthesis. ■

1. Schanzer A, Greenberg RK, Hevelone N, et al. Predictors of abdominal aortic aneurysm sac enlargement after endovascular repair. *Circulation*. 2011;123:2848-2855.
2. Oderich GS, Greenberg RK. Endovascular iliac branch devices for iliac aneurysms. *Perspect Vasc Surg Endovasc Ther*. 2011;23:166-172.
3. Haulon S, Greenberg RK, Pfaff K, et al. Branched grafting for aortoiliac aneurysms. *Eur J Vasc Endovasc Surg*. 2007;33:567-574.
4. Verzini F, Parlani G, Romano L, et al. Endovascular treatment of iliac aneurysm: concurrent comparison of side branch endograft versus hypogastric exclusion. *J Vasc Surg*. 2009;49:1154-1161.
5. Karthikesalingam A, Hinchliffe RJ, Holt PJ, et al. Endovascular aneurysm repair with preservation of the internal iliac artery using the iliac branch graft device. *Eur J Vasc Endovasc Surg*. 2010;39:285-294.
6. Wong S, Greenberg R, Eagleton M, et al. Endovascular repair of aortoiliac aneurysmal disease with the helical iliac branch device and the bifurcated-bifurcated branch device. 2013;58:861-869.
7. Schneider DB, Matsumura JS, Lee JT, et al. Prospective, multicenter study of endovascular repair of aortoiliac and iliac aneurysms using the Gore Iliac Branch Endoprosthesis. *J Vasc Surg*. 2017 May 27. [Epub ahead of print]

* The IBE has been designed, tested, and studied for modular use only with other GORE EXCLUDER Device components and is not approved for use with other stents or stent grafts.

Gustavo S. Oderich, MD

Professor of Surgery
Division of Vascular and Endovascular Surgery
Mayo Clinic
Rochester, Minnesota
oderich.gustavo@mayo.edu
Disclosures: Consultant to and receives research grants from Cook Medical, Gore & Associates, and GE Healthcare (all fees and grants paid to Mayo Clinic).

Giuliano de Almeida Sandri, MD

Clinical Research Fellow
Advanced Endovascular Aortic Program
Division of Vascular and Endovascular Surgery
Mayo Clinic
Rochester, Minnesota
Disclosures: None.

Emanuel Tenorio, MD, PhD

Clinical Research Fellow
Advanced Endovascular Aortic Program
Division of Vascular and Endovascular Surgery
Mayo Clinic
Rochester, Minnesota
Disclosures: None.



W. L. GORE & ASSOCIATES, INC.

Flagstaff, AZ 86004

+65.67332882 (Asia Pacific)

00800.6334.4673 (Europe)

800.437.8181 (United States)

928.779.2771 (United States)

goremedical.com

INDICATIONS FOR USE IN THE US: The GORE® EXCLUDER® Iliac Branch Endoprosthesis is indicated for use with the GORE® EXCLUDER® AAA Endoprosthesis to isolate the common iliac artery from systemic blood flow and preserve blood flow in the external iliac and internal iliac arteries in patients with a common iliac or aortoiliac aneurysm, who have appropriate anatomy, including: adequate iliac / femoral access; minimum common iliac diameter of 17 mm at the proximal implantation zone of the IBE; external iliac artery treatment diameter range of 6.5 – 25 mm and seal zone length of at least 10 mm; internal iliac artery treatment diameter range of 6.5 – 13.5 mm and seal zone length of at least 10 mm; adequate length from the lowest major renal artery to the internal iliac artery to accommodate the total endoprosthesis length, calculated by adding the minimum lengths of required components, taking into account appropriate overlaps between components. **Trunk-Ipsilateral Leg Endoprosthesis Components:** The Trunk-Ipsilateral Leg Endoprosthesis is intended to provide proximal seal and fixation for the endovascular repair of the aneurysm. For more information on the Trunk-Ipsilateral Leg Component indications for use and deployment, see the GORE® EXCLUDER® AAA Endoprosthesis *Instructions for Use*. **Contralateral Leg Endoprosthesis Components:** The Contralateral Leg Endoprosthesis is intended to bridge the GORE® EXCLUDER® Trunk-Ipsilateral Leg Component to the GORE® EXCLUDER® Iliac Branch Endoprosthesis. Additionally, the Contralateral Leg Endoprosthesis is intended to be used for distal extension of the Iliac Branch Component in the external iliac artery. The Iliac Branch Component can treat external iliac artery diameters up to 13.5 mm. This ability to extend the Iliac Branch Component distally with any Contralateral Leg Endoprosthesis expands the external iliac artery treatment range up to 25 mm. For more information on the Trunk-Ipsilateral Leg and Contralateral Leg Endoprosthesis Component indications for use and deployment, see the GORE® EXCLUDER® AAA Endoprosthesis *Instructions for Use*. **Aortic Extender Endoprosthesis and Iliac Extender Endoprosthesis Components:** The Aortic and Iliac Extender Endoprostheses can be used after deployment of the GORE® EXCLUDER® Iliac Branch and AAA Endoprostheses. These extensions are used when additional length and / or sealing for aneurysmal exclusion is desired. For more information on Aortic Extender and Iliac Extender indications for use and deployment, see the GORE® EXCLUDER® AAA Endoprosthesis *Instructions for Use*. **CONTRAINDICATIONS:** The GORE® EXCLUDER® Iliac Branch Endoprosthesis is contraindicated in: Patients with known sensitivities or allergies to the device materials. All components of the GORE® EXCLUDER® Iliac Branch Endoprosthesis and the GORE® EXCLUDER® AAA Endoprosthesis contain ePTFE, FEP, nitinol (nickel-titanium alloy), and gold. Patients with a systemic infection who may be at increased risk of endovascular graft infection. R_{ONLY}

INDICATIONS FOR USE UNDER CE MARK: Iliac Branch and Internal Iliac Components. The GORE® EXCLUDER® Iliac Branch Endoprosthesis (IBE) is intended to isolate the common iliac artery from systemic blood flow and preserve blood flow in the external iliac and internal iliac arteries in patients with a common iliac or aortoiliac aneurysm, who have appropriate anatomy, including: Adequate iliac / femoral access; Minimum common iliac diameter of 17 mm at the proximal implantation zone of the IBE; External iliac artery treatment diameter range of 6.5 – 25 mm and seal zone length of at least 10 mm; Internal iliac artery treatment diameter range of 6.5 – 13.5 mm and seal zone length of at least 10 mm. Trunk-Ipsilateral Leg and Contralateral Leg Endoprostheses are intended to provide proximal seal and fixation to the GORE® EXCLUDER® Iliac Branch Endoprosthesis following deployment of the GORE® EXCLUDER® Iliac Branch Endoprosthesis. For more information on the Trunk-Ipsilateral Leg and Contralateral Leg Endoprosthesis Component indications for use and deployment, see the GORE® EXCLUDER® AAA Endoprosthesis *Instructions for Use*. **Aortic Extender Endoprosthesis and Iliac Extender Endoprosthesis Components.** The Aortic and Iliac Extender Endoprostheses can be used after deployment of the GORE® EXCLUDER® Iliac Branch and AAA Endoprostheses. These extensions are used when additional length and / or sealing for aneurysmal exclusion is desired. For more information on Aortic Extender and Iliac Extender indications for use and deployment, see the GORE® EXCLUDER® AAA Endoprosthesis *Instructions for Use*. **CONTRAINDICATIONS:** The GORE® EXCLUDER® Iliac Branch Endoprosthesis is contraindicated in: Patients with known sensitivities or allergies to the device materials, and patients with a systemic infection who may be at increased risk of endovascular graft infection. Refer to *Instructions for Use* at goremedical.com for a complete description of all warnings, precautions, and adverse events. R_{ONLY}

Gore products referenced within are used within their FDA approved / cleared indications or are under investigation for the uses referenced within. Gore does not have knowledge of the indications and FDA approval / clearance status of non-Gore products. Gore makes no representations as to the surgical techniques, medical conditions or other factors that may be described in this article. The reader is advised to contact the manufacturer for current and accurate information.

Products listed may not be available in all markets.

AMPLATZ®, CODA®, FLEXOR®, INDY OTW®, LUNDERQUIST®, and TRACER METRO® are trademarks of Cook Medical, Inc. AMPLATZER® is a trademark of St. Jude Medical. GORE®, EXCLUDER®, and designs are trademarks of W. L. Gore & Associates.
© 2017 W. L. Gore & Associates, Inc. AW1265-EN1 AUGUST 2017