

RESTORING FLOW TO A BRACHIOAXILLARY AV GRAFT AFTER MULTIPLE FAILED PTA REVISIONS

Case submitted by Nicolas Mouawad, M.D.

Challenge

- 48-year-old male with end stage renal disease secondary to hypertensive nephrosclerosis and diabetic nephropathy
 - Relevant patient history:
 - Diabetes mellitus, chronic anemia, paroxysmal atrial fibrillation, coronary artery disease, hypertension, hyperlipidemia, COPD, tobacco use
 - Left brachioaxillary arteriovenous (AV) graft 4-7 mm implanted June 26, 2018. Two revisions, April 8, 2019 and August 23, 2019, each with an BD® ULTRASCORE® Focused Forced PTA Balloon followed by a 9 mm x 40 mm BD® LUTONIX® 035 Drug Coated Balloon PTA Catheter
- Presented after two failed percutaneous transluminal angioplasty (PTA) revisions of the venous anastomosis of an arteriovenous graft, preventing successful hemodialysis.

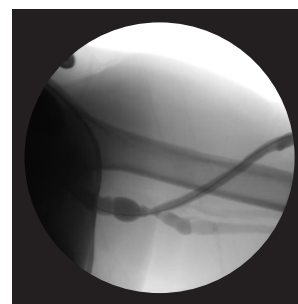


Image 1

Fistulography with recurrent stenosis noted at venous outflow anastomosis.

Procedure

- Planned definitive treatment with outflow stenting
- Advanced the TERUMO® RADIFOCUS® GLIDEWIRE® ADVANTAGE .035" Guidewire across the target lesion (*Image 2*)
- Pre-dilated the stenotic lesion with an 8 x 40 mm MEDTRONIC EVERCROSS PTA BALLOON Catheter (*Image 2*)
- Placed a 9 mm x 5 cm .035" guidewire compatible low profile VIABAHN® Device (*Image 3*)
- Post-dilated with a 9 x 40 mm MEDTRONIC EVERCROSS PTA BALLOON Catheter PTA (*Image 3*)

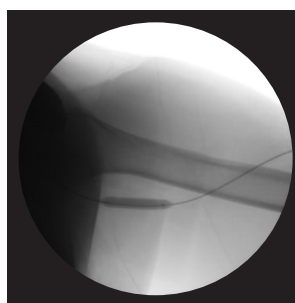


Image 2

Lesion preparation with pre-dilatation using 8 x 40 mm noncompliant balloon.

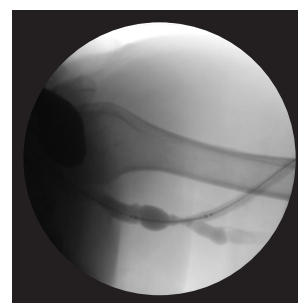


Image 3

Post-PTA outflow fistulography in preparation for GORE® VIABAHN® Endoprosthesis with Heparin Bioactive Surface deployment.

Images courtesy of Nicolas Mouawad, M.D. Used with permission.

* As used by Gore, Heparin Bioactive Surface refers to Gore's proprietary CBAS Heparin Surface.

Result

- Excellent outflow without any recurrent complication at eight months post-intervention.

Case Takeaways

The outcome of this case aligns to the well-established findings that the VIABAHN® Device offers value through reduced frequency of repeat interventions as compared to PTA.¹

Enhanced access and visibility in challenging anatomies is enabled by a low profile and radiopaque markers on the proximal and distal ends of the device.

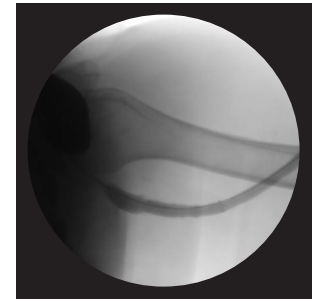



Image 4

Fistulogram following stent deployment with complete resolution of stenosis.

At eight months post-placement, the VIABAHN® Device has exceeded results achieved with prior PTA treatments; primary patency of the stent graft is maintained, with no circuit reinterventions post VIABAHN® Device placement to date.

Before placement of VIABAHN® Device	First intervention	Second intervention	Post placement of VIABAHN® Device	No recurrent complications reported
 AV graft implanted	Scoring balloon, DCB	Scoring balloon, DCB	VIABAHN® Device	
10 months	3 months	4 months	8 months	
June 2018	April 2019	August 2019	January 2020	August 2020

1. Mohr BA, Sheen AL, Roy-Chaudhury P, Schultz SR, Aruny JE; REVISE Investigators. Clinical and economic benefits of stent grafts in dysfunctional and thrombosed hemodialysis access graft circuits in the REVISE Randomized Trial. *Journal of Vascular & Interventional Radiology* 2019;30(2):203-211.e4. [https://www.jvir.org/article/S1051-0443\(18\)31772-X/fulltext](https://www.jvir.org/article/S1051-0443(18)31772-X/fulltext)

INDICATIONS FOR USE IN THE U.S.: The GORE® VIABAHN® Endoprosthesis is indicated for improving blood flow in patients with symptomatic peripheral arterial disease in superficial femoral artery de novo and restenotic lesions up to 270 mm in length with reference vessel diameters ranging from 4.0 – 7.5 mm, in superficial femoral artery in-stent restenotic lesions up to 270 mm in length with reference vessel diameters ranging from 4.0 – 6.5 mm, and in iliac artery lesions up to 80 mm in length with reference vessel diameters ranging from 4.0 – 12 mm. The GORE® VIABAHN® Endoprosthesis is also indicated for the treatment of stenosis or thrombotic occlusion at the venous anastomosis of synthetic arteriovenous (AV) access grafts.

CONTRAINDICATIONS: The GORE® VIABAHN® Endoprosthesis with Heparin Bioactive Surface is contraindicated for noncompliant lesions where full expansion of an angioplasty balloon catheter was not achieved during pre-dilatation, or where lesions cannot be dilated sufficiently to allow passage of the delivery system. Do not use the GORE® VIABAHN® Endoprosthesis with Heparin Bioactive Surface in patients with known hypersensitivity to heparin, including those patients who have had a previous incidence of Heparin-Induced Thrombocytopenia (HIT) type II. Refer to Instructions for Use at eifu.goremedical.com for a complete description of all applicable indications, warnings, precautions and contraindications for the markets where this product is available. Rx Only

This content is for informational purposes only, is not advice or a guarantee of outcome. It is not a substitute for professional medical advice, diagnosis or treatment. Individual results and/or treatment may vary based upon the circumstances, the patient's specific situation, and the healthcare provider's medical judgment.

 Consult Instructions for Use at eifu.goremedical.com

Products listed may not be available in all markets.

BD, LUTONIX and ULTRASCORE are trademarks of Becton, Dickinson and Company. MEDTRONIC and EVERCROSS are trademarks of Medtronic, Inc. TERUMO and RADIFOCUS are trademarks of Terumo Medical Corporation.

GORE, Together, improving life, VIABAHN and designs are trademarks of W. L. Gore & Associates. © 2020, 2021 W. L. Gore & Associates, Inc. 2157166-EN FEBRUARY 2021

W. L. Gore & Associates, Inc.
goremedical.com

Asia Pacific +65 67332882 Australia/New Zealand 1800 680 424 Europe 00800 6334 4673
United States Flagstaff, AZ 86004 800 437 8181 928 779 2771

