Instructions for using this presentation:

This presentation deck is applicable to the GORE® VIABAHN® Endoprosthesis with HEPARIN Bioactive Surface* in complex Peripheral Artery Disease (PAD).

You may tailor this slide set to meet your needs.

- Slides may be rearranged for order (to clarify the intended message).
- Slides may be deleted or hidden, except if the slides contain disclaimers or other Gore-indicated mandatory content.
- As the speaker engaged by Gore, you may add additional slides to provide on-label studies or other supplementary on-label content.
- If during the course of your presentation, you are asked questions that require you to discuss information different from the device indications and techniques specified in the IFU, you agree to clearly state that this information, such as treatment or deployment information not included in the IFU is "off-label" or "not indicated" and respond to the question in a similar manner.

Please delete this instruction slide before presenting.

* As used by Gore, Heparin Bioactive Surface refers to Gore's proprietary CBAS Heparin Surface.

GORE, VIABAHN and designs are trademarks of W. L. Gore & Associates. © 2021 W. L. Gore & Associates, Inc. 21309303-EN NOVEMBER 2021

GORE® VIABAHN® Endoprosthesis with Heparin Bioactive Surface* in Complex Superficial Femoral Artery (SFA) Disease

Presenters Name / Date

* As used by Gore, Heparin Bioactive Surface refers to Gore's proprietary CBAS Heparin Surface.

CBAS is a trademark of Carmeda AB, a wholly owned subsidiary of W. L. Gore & Associates, Inc.
GORE, VIABAHN and designs are trademarks of W. L. Gore & Associates. © 2021 W. L. Gore & Associates, Inc.

Physician disclosure

© 2021 W. L. Gore & Associates, Inc.

Agenda

- Challenges associated with complex peripheral artery disease (PAD) in the superficial femoral artery (SFA)
- Overview of the GORE® VIABAHN® Endoprosthesis with Heparin Bioactive Surface and recent clinical evidence:
  - Gore Japan IDE Clinical Study
  - Gore Japan Post Market Clinical Follow-up (PMCF) data
  - VANQUISH Clinical Study
- Case studies
- Q & A

GORE, VIABAHN and designs are trademarks of W. L. Gore & Associates. © 2021 W. L. Gore & Associates, Inc.

Treating Complex PAD in the SFA

© 2021 W. L. Gore & Associates, Inc.

Femoral-popliteal lesions

TASC II guidelines recommend surgery for type C and D lesions[1]

Surgery

Type C lesions:

- Multiple stenosis or occlusions totaling > 15 cm with or without heavy calcification
- Recurrent stenoses or occlusions that need treatment after two endovascular interventions



Type D lesions:

- Chronic total occlusion (CTO) of common femoral artery (CFA) or SFA (> 20 cm, involving the popliteal artery)
- CTO of popliteal artery and proximal trifurcation vessels

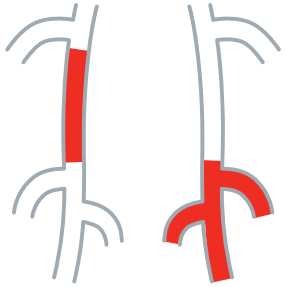

1. Norgren L, Hiatt WR, Dormandy JA, Nehler MR, Harris KA, Fowkes FG; TASC II Working Group. Inter-Society consensus for the management of peripheral arterial disease (TASC II). *Journal of Vascular Surgery* 2007;45(1)Supplement S:S5-S67.

© 2021 W. L. Gore & Associates, Inc.

The role of stent grafts in complex PAD

- Numerous studies have reported excellent outcomes with stent grafts.*
  - TASC II C and D lesions.
  - SFA long lesions.
  - In-stent restenosis.
  - Highly calcified.
  - CTO.
- Endoluminal bypass with stent grafts offer advantages for complex lesions.*
  - Exclude plaque and prevent in-stent neointimal hyperplasia.
  - Decrease risk of complications stemming from distal embolization, perforation, rupture or dissection.
  - Promote hemodynamic flow via a new flow lumen.
- Society for Vascular Surgery guidelines recommend stent grafts in instances of severe calcification at risk of vessel rupture.[1]

* GORE® VIABAHN® Endoprosthesis. W. L. Gore & Associates website. Accessed July 29, 2020. https://www.goremedical.com/viabahn/references

1. Society for Vascular Surgery Lower Extremity Guidelines Writing Group, Conte MS, Pomposelli FB, *et al.* Society for Vascular Surgery practice guidelines for atherosclerotic occlusive disease of the lower extremities: management of asymptomatic disease and claudication. *Journal of Vascular Surgery* 2015;61(3)Supplement:2S-41S. https://www.sciencedirect.com/science/article/pii/S0741521414022848

© 2021 W. L. Gore & Associates, Inc.

Consider the complexity and demands of treating long length lesions of the SFA and CTOs

- Lesion length is a predictor of patency outcomes for several treatment modalities.
  - Lesion length has been shown to be an independent predictor of restenosis.[1]
  - Complications increase with lesion length.[2–6]
- CTOs can increase the need for provisional stenting.[2]
  - In the Medtronic IN.PACT Global Study, treatment of CTOs increased the rate of provisional stenting by 85 percent.[2]
  - Although a rare complication, the risk of distal embolization has been shown to increase when treating a CTO.[7,8]
  - Limited comparison data between newer endovascular technologies compared to surgical bypass, the current recommended treatment for CTOs.[9]

1. Iida O, Takahara M, Soga Y, *et al*; ZEPHYR Investigators. 1-year results of the ZEPHYR Registry (Zilver PTX for the Femoral Artery and Proximal Popliteal Artery): predictors of restenosis. *JACC: Cardiovascular Interventions* 2015;8(8):1105-1112.
2. Scheinert D, Micari A, Brodmann M, *et al*; IN.PACT Global Study Investigators. Drug-coated balloon treatment for femoropopliteal artery disease. *Circulation: Cardiovascular Interventions* 2018;11(10):e005654.
3. Iida O, Nanto S, Uematsu M, Ikeoka K, Okamoto S, Nagata S. Influence of stent fracture on the long-term patency in the femoro-popliteal artery. *JACC : Cardiovascular Interventions* 2009;2(7):665-671.
4. Scheinert D, Scheinert S, Sax J, *et al.* Prevalence and clinical impact of stent fractures after femoropopliteal stenting. *Journal of the American College of Cardiology* 2005;45(2):312-315.
5. U.S. Food and Drug Administration. Center for Devices and Radiological Health. FDA Summary of Safety and Effectiveness Data. GORE TIGRIS Vascular Stent. P160004. http://www.accessdata.fda.gov/cdrh_docs/pdf16/P160004B.pdf. Published July 27, 2016. Accessed July 17, 2018.
6. W. L. Gore & Associates, Inc. Evaluation of the GORE® TIGRIS® Vascular Stent in the Treatment of Atherosclerotic Lesions of the Superficial Femoral and Proximal Popliteal Arteries. [Final Post-Approval Study Report-Executive Summary]. Flagstaff, AZ: W. L. Gore & Associates, Inc; 2017. MD165299.
7. Wu W, Hua S, Li Y, *et al.* Incidence, risk factors, treatment and prognosis of popliteal artery embolization in the superficial femoral artery interventions. PLoS One 2014;9(9):e107717.
8. Shrikhande GV, Khan SZ, Hussain HG, Dayal R, McKinsey JF, Morrissey N. Lesion types and device characteristics that predict distal embolization during percutaneous lower extremity interventions. *Journal of Vascular Surgery* 2011;53(2):347-352.
9. Norgren L, Hiatt WR, Dormandy JA, Nehler MR, Harris KA, Fowkes FG; TASC II Working Group. Inter-Society Consensus for the Management of Peripheral Arterial Disease (TASC II). *Journal of Vascular Surgery* 2007;45(1)Supplement:S5-S67.

MEDTRONIC and IN.PACT are trademarks of Medtronic, Inc.
© 2021 W. L. Gore & Associates, Inc.

Overview of the GORE® VIABAHN® Endoprosthesis with Heparin Bioactive Surface and Recent Clinical Evidence

GORE, VIABAHN and designs are trademarks of W. L. Gore & Associates. © 2021 W. L. Gore & Associates, Inc.

VIABAHN® Device — More than 20 years of innovation and experience

- Proven patency*
- Fewer reinterventions*
- Demonstrated durability*
- Broadly indicated*



1996
Original GORE® HEMOBAHN® Endoprosthesis introduced in Europe

2002
Original device introduced in U.S. as GORE® VIABAHN® Endoprosthesis

2003
TIP to HUB deployment introduced on 6–8 mm devices

2005
6–8 mm devices in U.S. receive FDA approval for SFA indication

2007
GORE® VIABAHN® Endoprosthesis with Heparin Bioactive Surface introduced in U.S.

5–8 mm devices decreased in profile by one French size

2008
All device sizes receive FDA approval for Iliac artery indication

2009
Laser technology enables the new contoured edge at proximal end

9–13 mm devices introduced with 0.035" guidewire compatibility

2011
GORE® VIABAHN® Endoprosthesis with Heparin Bioactive Surface 5–8 mm devices decreased in profile by one French size

2013
FDA approval for Revision of Arteriovenous Access Grafts

25 cm Length: Longest stent graft introduced in U.S.

2014
5-7 mm devices receive FDA approval for treatment of in-stent restenosis in the SFA

Radiopaque markers on endoprosthesis introduced on 5–8 mm devices

2016
7.5 cm length introduced in U.S. for 5–9 mm devices

2020
Up to 3 Fr size reduction in profile and addition of radiopaque markers on 9–13 mm devices

* GORE® VIABAHN® Endoprosthesis. W. L. Gore & Associates website. Accessed July 29, 2020. https://www.goremedical.com/viabahn/references

© 2020 W. L. Gore & Associates, Inc.

GORE, HEMOBAHN, VIABAHN and designs are trademarks of W. L. Gore & Associates. © 2021 W. L. Gore & Associates, Inc.

Technology and clinical benefits of the VIABAHN® Device

Ultra-thin wall ePTFE tube
Covers and excludes disease

Single wire nitinol frame
Flexibility; trackability; fracture resistance

Radiopaque markers
Enhances visibility

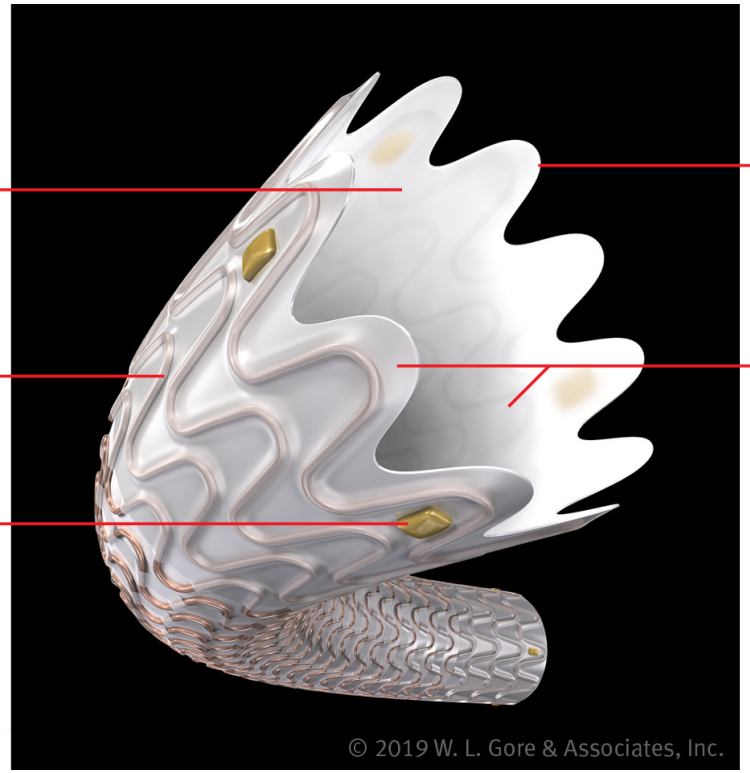

Contoured proximal edge
Reduces in-folding

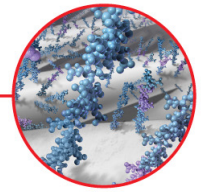

CBAS Heparin Surface
Lasting thromboresistance[1]

Lengths: 2.5 / 5 / 7.5 / 10 / 15 / 25 cm

Diameters: 5–13 mm

Guidewires: .035" (5–13 mm)
.014" / .018" (5–8 mm)

1. CBAS Heparin Surface. W.L. Gore & Associates Web site. https://www.goremedical.com/cbas/references. Accessed January 28, 2021.

CBAS is a trademark of Carmeda AB, a wholly owned subsidiary of W. L. Gore & Associates, Inc.
GORE, VIABAHN and designs are trademarks of W. L. Gore & Associates. © 2021 W. L. Gore & Associates, Inc.

80% average primary patency in complex SFA disease at one year in over 1,000 lesions

Trial name	Number of lesions	Mean lesion length (cm)	CTOs (%)	One-year primary patency (%)	One-year secondary patency (%)
SuperB Study[1]	63	23	75*	65	86
Gore VIPER Clinical Study[2]	119	19	56	73	92
VIASTAR Trial[3]	66	19	79	78	90
25cm Trial[4]	71	27	93	67	97
Japan IDE Study[5]	103	22	66	88	98
Japan Post Market Clinical Study[6]	324	24	70	86	95
VANQUISH Study[†,7]	343	25	71	80	NR
Combined results (weighted average, as appropriate)	1,089	23	71	80	94

* CTO percentage defined as percentage of TASC II D.
† Full lesion coverage cohort only.

1. Reijnen MMPJ, van Walraven LA, Fritschy WM, *et al.* 1-year results of a multicenter randomized controlled trial comparing heparin-bonded endoluminal to femoropopliteal bypass. *JACC: Cardiovascular Interventions* 2017;10(22):2320-2331.
2. Saxon RR, Chervu A, Jones PA, *et al.* Heparin bonded, expanded polytetrafluoroethylene lined stent graft in the treatment of femoropopliteal artery disease: 1 year results of the VIPER (Viabahn Endoprosthesis with Heparin Bioactive Surface in the Treatment of Superficial Femoral Artery Obstructive Disease) Trial. *Journal of Vascular & Interventional Radiology* 2013;24(2):165 173.
3. Lammer J, Zeller T, Hausegger KA, *et al.* Sustained benefit at 2 years for covered stents versus bare-metal stents in long SFA lesions: the VIASTAR Trial. *Cardiovascular & Interventional Radiology* 2015;38(1):25-32.
4. Zeller T, Peeters P, Bosiers M, *et al*. Heparin-bonded stent-graft for the treatment of TASC II C and D femoropopliteal lesions: the Viabahn-25 cm Trial. *Journal of Endovascular Therapy* 2014;21(6):765-774.
5. Ohki T, Kichikawa K, Yokoi H, *et al.* Long-term results of the Japanese multicenter Viabahn trial of heparin bonded endovascular stent grafts for long and complex lesions in the superficial femoral artery. *Journal of Vascular Surgery*. In press.
6. Iida 0. Twelve-month outcomes from the Japanese post-market surveillance study of the GORE® VIABAHN® Endoprosthesis as treatment for symptomatic peripheral arterial disease in the superficial femoral arteries. Presented at LEIPZIG Interventional Course (LINC)2021; January 25-29, 2021; Leipzig, Germany.
7. Iida O, Takahara M, Soga Y, *et al*; VANQUISH Investigators. One-year outcomes of heparin-bonded stent-graft therapy for real-world femoropopliteal lesions and the association of patency with the prothrombotic state based on the prospective, observational, multicenter Viabahn Stent-Graft Placement for Femoropopliteal Diseases Requiring Endovascular Therapy (VANQUISH) Study. *Journal of Endovascular Therapy* 2021;28(1):123-131.

© 2021 W. L. Gore & Associates, Inc.

Gore Japan IDE Clinical Study

© 2021 W. L. Gore & Associates, Inc.

Gore Japan IDE Clinical Study: Study Overview[1]

- Objective
  - To test the safety, efficacy and invasiveness of the GORE® VIABAHN® Endoprosthesis with Heparin Bioactive Surface for the treatment of long/complex superficial femoral artery (SFA) lesions (≥ 10 cm) that currently may require bypass.
- Design
  - Single-arm, prospective, 15 sites, 103 patients for analysis. Invasiveness compared to retrospective review of bypass patients. Core laboratory adjudicated.

1. Ohki T, Kichikawa K, Yokoi H, *et al.* Long-term results of the Japanese multicenter Viabahn trial of heparin bonded endovascular stent grafts for long and complex lesions in the superficial femoral artery. *Journal of Vascular Surgery*. In press.

GORE, VIABAHN and designs are trademarks of W. L. Gore & Associates. © 2021 W. L. Gore & Associates, Inc.

Gore Japan IDE Clinical Study: Study Endpoints[1–3]

- Primary endpoints
  - **Primary assisted patency at one-year:** A stent graft that had not occluded at any time (although target lesion revascularization [TLR] could have been performed for stenosis).[1]
  - **Post-procedure hospital stay:** Compared to historical bypass control.[2]
  - **Freedom from general anesthesia:** Compared to historical bypass control.[2]
- Secondary endpoints
  - **Safety:** Adverse events. Freedom from death, Target Vessel Revascularization (TVR)[3], and major amputation of the treated limb through 30 days post-procedure.[1]
  - **Efficacy:** Technical success, primary patency, secondary patency, freedom from TLR (fTLR), freedom from TVR (fTVR), limb salvage, clinical success, stent fracture, ankle-brachial index (ABI) — or toe-brachial index (TBI), quality of Life (QoL).[1]
  - **Invasiveness:** Freedom from blood transfusion.[2]
- Patency definitions
  - **Primary patency:** Peak systolic velocity ratio < 2.5 without TLR in treated lesions.[1]
  - **Primary assisted patency (PAP):** A stent graft that had not occluded at any time (although target lesion revascularization (TLR) could have been performed for stenosis).[1]

1. Ohki T, Kichikawa K, Yokoi H, *et al.* Long-term results of the Japanese multicenter Viabahn trial of heparin bonded endovascular stent grafts for long and complex lesions in the superficial femoral artery. *Journal of Vascular Surgery*. In press.
2. Ohki T, Kichikawa K, Yokoi H, *et al.* Outcomes of the Japanese multicenter Viabahn trial of endovascular stent grafting for superficial femoral artery lesions. *Journal of Vascular Surgery* 2017;66(1):130-142.e1
3. Ohki T. 2 year results of the VIABAHN Japan IDE trial for complex SFA lesions. Presented at the Leipzig Interventional Course (LINC); January 24-27, 2017; Leipzig, Germany.

© 2021 W. L. Gore & Associates, Inc.

Majority of patients were older men with a history of smoking and diabetes[1,2]

Number of subjects enrolled	**N = 103**
Age (years)	**n**
Mean (Std Dev)	74.2 (7.0)
Median	75
Min–Max	55–91
Gender	**n (%)**
Male	85 (82.5%)
Female	18 (17.5%)
Smoking history	**n (%)**
Current smoker	29 (28.2%)
Former smoker	52 (50.5%)
Never smoked	22 (21.4%)

Diabetes mellitus	**n (%)**
Non-diabetic	41 (39.8%)
Diabetic	62 (60.2%)
ABI	**(N = 102)**
Mean (Std Dev)	.64 ± .12
Median	.62
Min–Max	.38–.89
Baseline Rutherford Category	**(N = 103)**
Category 2 — Moderate claudication	45 (43.7%)
Category 3 — Severe claudication	55 (53.4%)
Category 4 — Ischemic rest pain	1 (1.0%)
Category 5 — Minor tissue loss	2 (1.9%)

© 2019 W. L. Gore & Associates, Inc.

1. Ohki T, Kichikawa K, Yokoi H, *et al.* Long-term results of the Japanese multicenter Viabahn trial of heparin bonded endovascular stent grafts for long and complex lesions in the superficial femoral artery. *Journal of Vascular Surgery*. In press.
2. Ohki T. 2 year results of the VIABAHN Japan IDE trial for complex SFA lesions. Presented at the Leipzig Interventional Course (LINC); January 24-27, 2017; Leipzig, Germany.

© 2021 W. L. Gore & Associates, Inc.

Evaluated in long, complex lesions generally suitable for bypass[1,2]

Mean target lesions length (cm) ± SD	**21.8 ± 5.8**
Total occlusions	**67 (65.7%)**
TASC classification	
TASC II A	0 (.0%)
TASC II B	16 (15.5%)
TASC II C	75 (72.8%)
TASC II D	12 (11.7%)
SFA lesion location (lesion may cross over)[2]	
Proximal	72 (69.9%)
Mid	99 (96.1%)
Distal	77 (74.8%)

© 2019 W. L. Gore & Associates, Inc.

1. Ohki T, Kichikawa K, Yokoi H, *et al.* Long-term results of the Japanese multicenter Viabahn trial of heparin bonded endovascular stent grafts for long and complex lesions in the superficial femoral artery. *Journal of Vascular Surgery*. In press.
2. Ohki T. 2 year results of the VIABAHN Japan IDE trial for complex SFA lesions. Presented at the Leipzig Interventional Course (LINC); January 24-27, 2017; Leipzig, Germany.

© 2021 W. L. Gore & Associates, Inc.

Japan IDE Clinical Study: 79.1% freedom from TLR at five years[1]

Primary endpoint outcomes[2]

94% Primary assisted patency through one year

3.5 ± 2.9 days mean post-procedural length of stay

100% Freedom from general anesthesia

Freedom from TLR

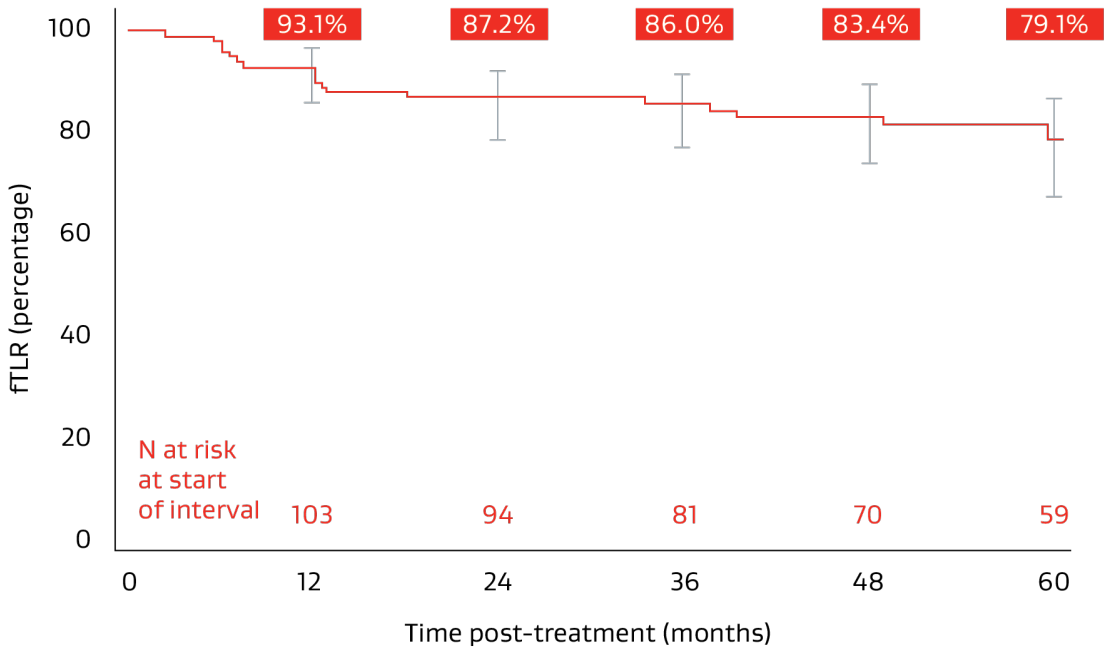

© 2020 W. L. Gore & Associates, Inc.

1. Ohki T, Kichikawa K, Yokoi H, *et al.* Long-term results of the Japanese multicenter Viabahn trial of heparin bonded endovascular stent grafts for long and complex lesions in the superficial femoral artery. *Journal of Vascular Surgery*. In press.
2. Ohki T, Kichikawa K, Yokoi H, *et al.* Outcomes of the Japanese multicenter Viabahn trial of endovascular stent grafting for superficial femoral artery lesions. *Journal of Vascular Surgery* 2017;66(1):130-142.e1

© 2021 W. L. Gore & Associates, Inc.

Additional five-year outcomes[1]

- 100% limb salvage
- No stent fractures identified by core laboratory
- No reported cases of acute limb ischemia
- One bypass surgery through five years

Patient population: n = 61 at five-year follow-up.

1. Ohki T, Kichikawa K, Yokoi H, et al. Long-term results of the Japanese multicenter Viabahn trial of heparin bonded endovascular stent grafts for long and complex lesions in the superficial femoral artery. *Journal of Vascular Surgery*. In press.

© 2021 W. L. Gore & Associates, Inc.

Gore Japan Post Market Clinical Study

© 2021 W. L. Gore & Associates, Inc.

Gore Japan Post Market Clinical Study: Study Overview[1]

- Objective
  - To confirm device efficacy and safety in the clinical setting after the launch of the GORE® VIABAHN® Endoprosthesis with Heparin Bioactive Surface for the treatment of symptomatic peripheral arterial disease in the superficial femoral arteries (SFA).
- Design
  - Single-arm, prospective, 64 sites, 321 patients for analysis.
  - Expected target patients: SFA lesions ≥ 10 cm in length with reference vessel diameters ranging from 4.0 to 7.5 mm.
  - Pre-specified follow-up: One month; one, two, three, four and five years.

1. Iida O. Twelve-month outcomes from the Japanese post-market surveillance study of the GORE® VIABAHN® Endoprosthesis as treatment for symptomatic peripheral arterial disease in the superficial femoral arteries. Presented at the Leipzig Interventional Course (LINC); January 22-29, 2021; Leipzig, Germany.

GORE, VIABAHN and designs are trademarks of W. L. Gore & Associates. © 2021 W. L. Gore & Associates, Inc.

Gore Japan Post Market Clinical Study: Study Endpoints[1]

- Effectiveness endpoints
  - Primary, primary assisted and secondary patencies.
  - Limb salvage: Absence of major amputation (assessed at 12 months).
  - Freedom from target lesion revascularization (fTLR).
  - Clinical improvement: Change in ABI relative to baseline assessment.
- Safety endpoints
  - Occurrence of device- or procedure-related serious adverse events (SAEs) through the end of the 12 month visit window (395 days) and occurrence of stent fracture at 12-month assessment.

1. Iida O. Twelve-month outcomes from the Japanese post-market surveillance study of the GORE® VIABAHN® Endoprosthesis as treatment for symptomatic peripheral arterial disease in the superficial femoral arteries. Presented at the Leipzig Interventional Course (LINC); January 22-29, 2021; Leipzig, Germany.

© 2021 W. L. Gore & Associates, Inc.

Patient population and limb characteristics[1]

Patient characteristics	N = 321
Age, years (N=318)	73.9 ± 8.7
Male (N=321)	248 (77.3)
Diabetes (N=321)	176 (54.8)
Renal failure requiring dialysis (N=321)	74 (23.1)
Smoking history (N=306)	
Current smoker	79 (25.8)
Former smoker	153 (50.0)
Chronic limb-threatening ischemia	85 (26.5)

Limb characteristics	N = 324
Prior PAD treatment (N=324)	72 (22.2)
TASC C/D (N=320)	277 (86.6)
ABI (N=292)	0.60 ± 0.16
Lesion length, cm (N=324)	23.6 ± 6.6
Total occlusion (N=324)	228 (70.4)
Moderate/severe lesion calcification (N=324)	129 (39.8)

© 2021 W. L. Gore & Associates, Inc.

1. Iida O. Twelve-month outcomes from the Japanese post-market surveillance study of the GORE® VIABAHN® Endoprosthesis as treatment for symptomatic peripheral arterial disease in the superficial femoral arteries. Presented at the Leipzig Interventional Course (LINC); January 22-29, 2021; Leipzig, Germany.

© 2021 W. L. Gore & Associates, Inc.

Effectiveness outcomes[1]

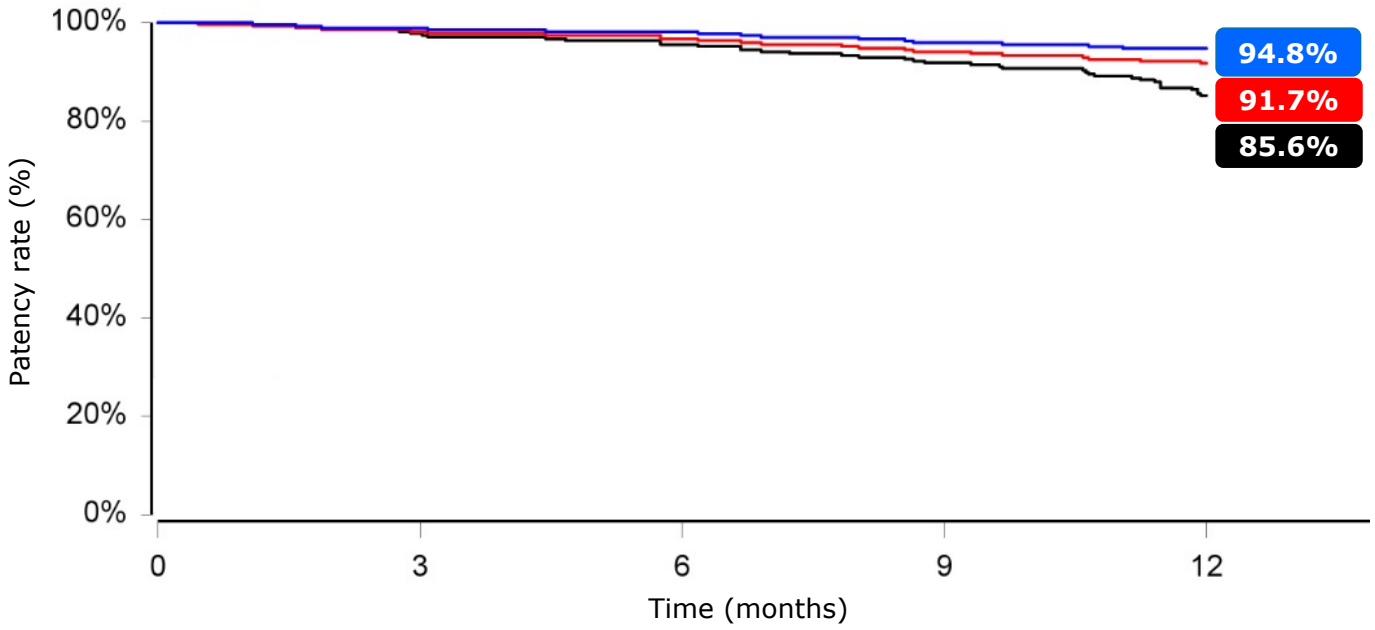

No. as risk, %, (C.I.)	Days (0-37)	Days (37-121)	Days 121-212)	Days (212-365)
Secondary Patency	304, 99.6% (97.5-99.9%)	274, 98.5% (96.2-99.4%)	265, 96.7% (93.7-98.3%)	259, 94.8% (90.9-96.6%)
Primary Assisted Patency	304, 99.3% (97.3-99.8%)	272, 97.8% (95.2-99.0%)	262, 95.6% (92.4-94.5%)	255, 91.7% (87.7-94.5%)
Primary Patency	304, 99.3% (97.3-99.8%)	273, 97.1% (94.3-98.5%)	261, 94.1% (90.6 -96.4%)	252, 85.6% (80.3-89.0%)

1. Iida O. Twelve-month outcomes from the Japanese post-market surveillance study of the GORE® VIABAHN® Endoprosthesis as treatment for symptomatic peripheral arterial disease in the superficial femoral arteries. Presented at the Leipzig Interventional Course (LINC); January 22-29, 2021; Leipzig, Germany.

© 2021 W. L. Gore & Associates, Inc.

Freedom from target lesion revascularization[1]

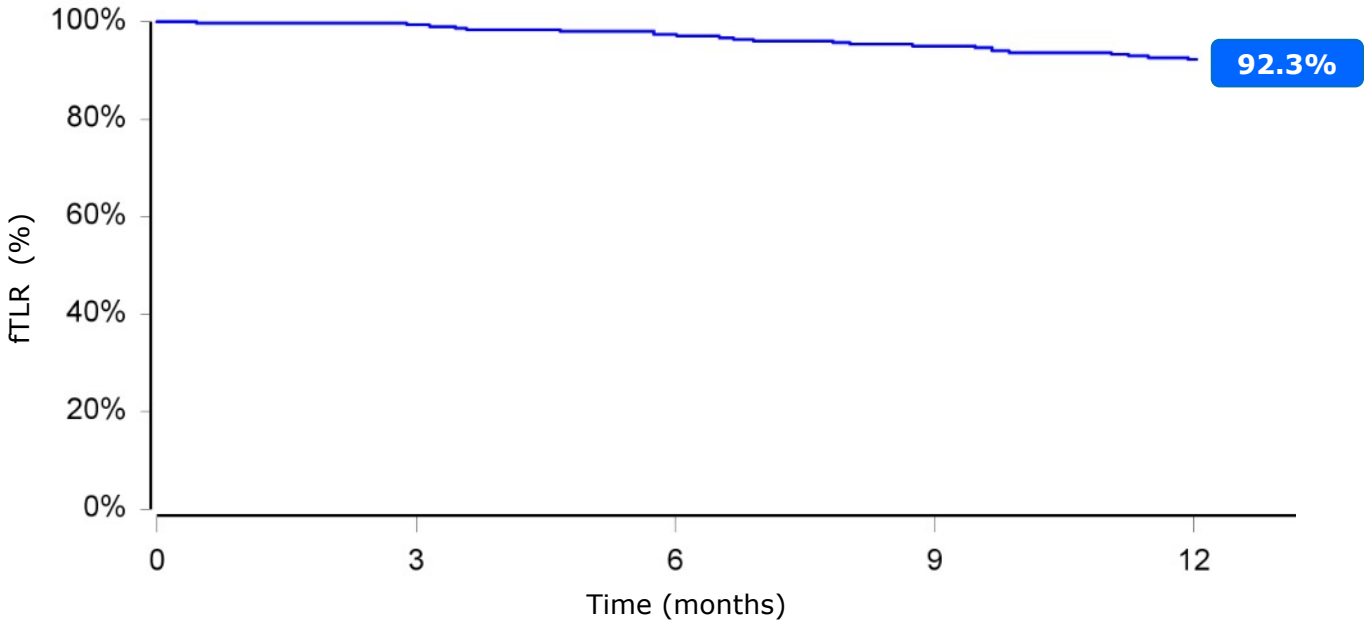

No. as risk, %, (C.I.)	Days (0-30)	Days (30-90)	Days (90-180)	Days (180-365)
No. as risk, %, (C.I.)	324, 99.7% (97.8-100%)	313, 99.4% (97.5-99.8%)	302, 97.4% (94.8-98.7%)	295, 92.3% (88.6-94.8%)

1. Iida O. Twelve-month outcomes from the Japanese post-market surveillance study of the GORE® VIABAHN® Endoprosthesis as treatment for symptomatic peripheral arterial disease in the superficial femoral arteries. Presented at the Leipzig Interventional Course (LINC); January 22-29, 2021; Leipzig, Germany.

© 2021 W. L. Gore & Associates, Inc.

Effectiveness in real-world patient populations[1]

Hemodialysis vs non-hemodialysis patients

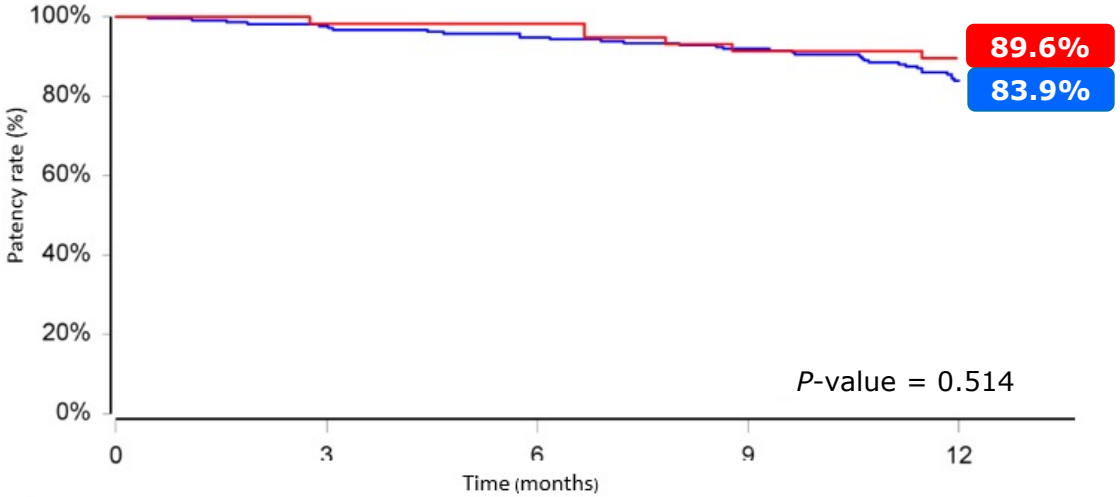

No. as risk, %, (C.I.)	Days (0-37)	Days (37-121)	Days (121-212)	Days (212-365)
Non-hemodialysis	234, 99.1% (96.5-99.8%)	211, 96.7% (93.3-98.4%)	203, 93.9% (89.7-96.4%)	196, 83.9% (78.2-88.3%)
Hemodialysis	70, 100% (100-100%)	61, 98.3% (88.4-99.8%)	57, 94.8 (84.8-98.3%)	55, 89.6% (78.2-95.2%)

CLI (Rutherford 4–6) vs IC (Rutherford 1–3)

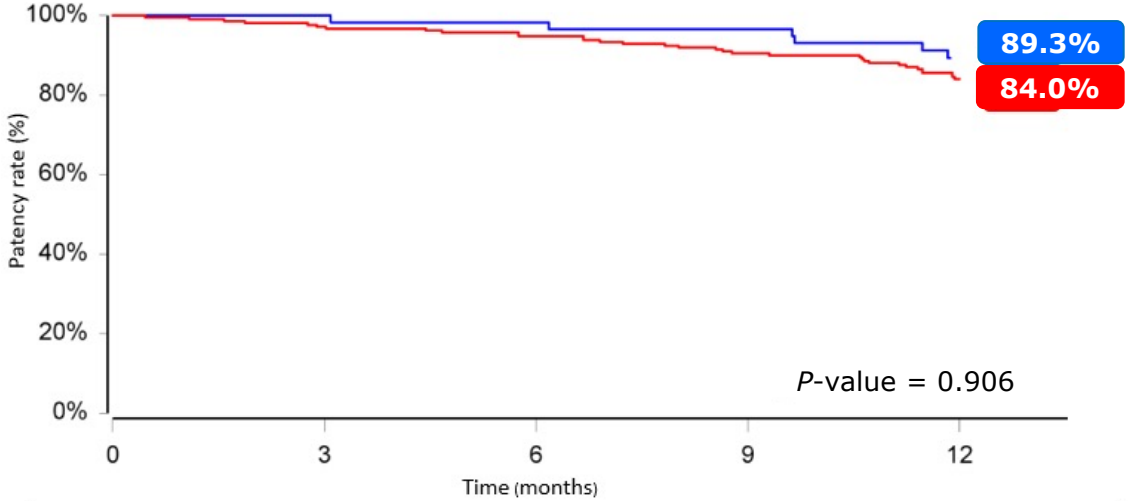

No. as risk, %, (C.I.)	Days (0-37)	Days (37-121)	Days (121-212)	Days (212-365)
CLI (Rutherford 4-6)	76, 100% (100-100%)	61, 98.3% (88.4-99.8%)	57, 96.6% (89.9-99.1%)	56, 89.3% (77.7-95.1%)
IC (Rutherford 1-3)	228, 99.1% (96.4-99.8%)	211, 96.7% (93.2-98.4%)	203, 93.4% (89.1-96.0%)	195, 84.0% (78.3-88.4%)

1. Iida O. Twelve-month outcomes from the Japanese post-market surveillance study of the GORE® VIABAHN® Endoprosthesis as treatment for symptomatic peripheral arterial disease in the superficial femoral arteries. Presented at the Leipzig Interventional Course (LINC); January 22-29, 2021; Leipzig, Germany.

© 2021 W. L. Gore & Associates, Inc.

Effectiveness in real-world patient populations[1]

Moderate/severe vs. none/mild calcification

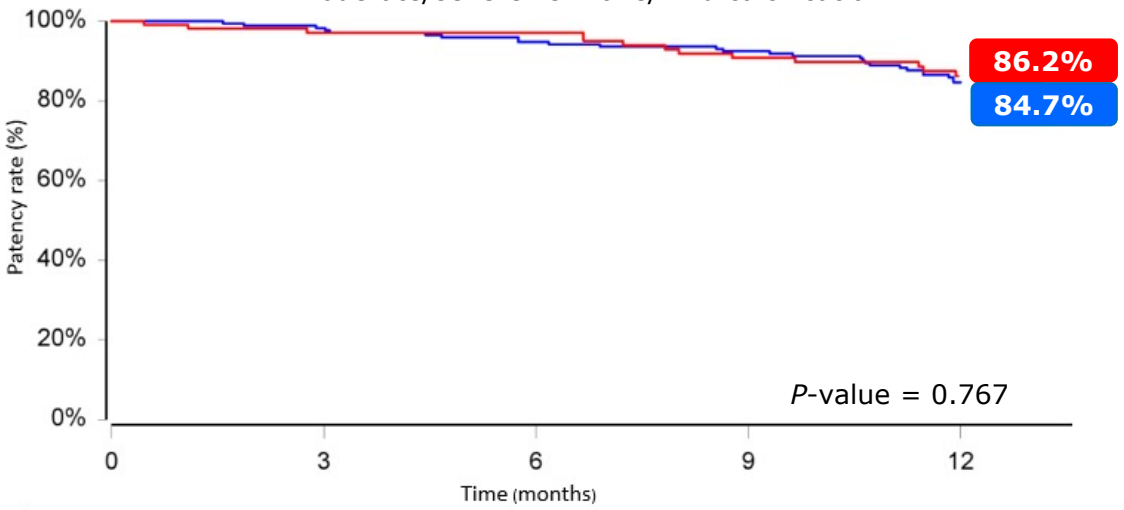

No. as risk, %, (C.I.)	Days (0-37)	Days (37-121)	Days (121-212)	Days (212-365)
None/Mild Calcification	185, 100% (100-100%)	175, 97.1% (93.2-98.8%)	167, 93.6% (88.8-96.4%)	161, 84.7% (78.3-89.3%)
Moderate/Severe Calcification	119, 98.2% (92.2-99.5%)	97, 97.1% (91.4-97.9%)	93, 95.0% (88.4-97.9%)	90, 86.2% (77.4-91.8%)

Lesion length

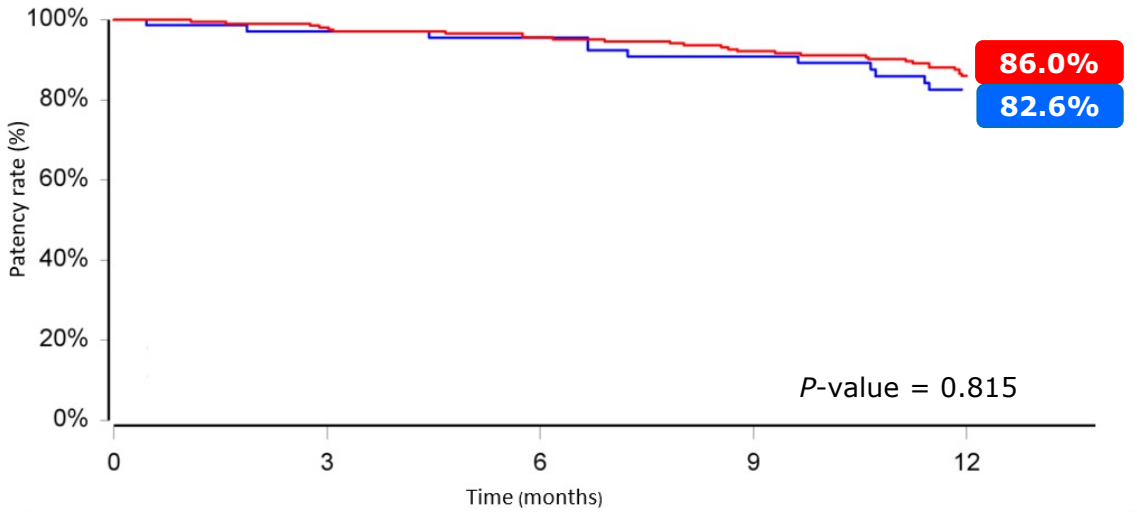

No. as risk, %, (C.I.)	Days (0-37)	Days (37-121)	Days (121-212)	Days (212-365)
< 20cm	74, 98.6% (90.7-99.8%)	66, 97.1% (88.8-99.3%)	62, 92.4% (82.7-96.8%)	59, 82.6% (70.7-90.0%)
≥ 20cm	230, 99.5% (96.7-99.9%)	206, 97.1% (93.6-98.7%)	198, 94.6% (90.5-97.0%)	192, 86.0% (80.3-90.1%)

1. Iida O. Twelve-month outcomes from the Japanese post-market surveillance study of the GORE® VIABAHN® Endoprosthesis as treatment for symptomatic peripheral arterial disease in the superficial femoral arteries. Presented at the Leipzig Interventional Course (LINC); January 22-29, 2021; Leipzig, Germany.

© 2021 W. L. Gore & Associates, Inc.

The VANQUISH Study

© 2021 W. L. Gore & Associates, Inc.

VANQUISH Study: Study Overview[1]

- Objective
  - To evaluate the one-year primary patency of the GORE® VIABAHN® Endoprosthesis with Heparin Bioactive Surface in real-world settings and explore the risk factors, including the prothrombotic state, for loss of patency.
- Design
  - Single-arm, prospective, 19 sites, 371 patients (424 limbs) for analysis.
  - Target patients: ≥ 50% stenosis and a lesion length ≥ 10 cm evaluated using duplex ultrasound, computed tomography angiography or diagnostic angiography.
  - Assessments: Vessel morphology evaluated using intravascular ultrasound (IVUS) during endovascular therapy (EVT), and preprocedural prothrombotic state was assessed by measuring platelet reactivity.

1. Iida O, Takahara M, Soga Y, *et al*; VANQUISH Investigators. One-year outcomes of heparin-bonded stent-graft therapy for real-world femoropopliteal lesions and the association of patency with the prothrombotic state based on the prospective, observational, multicenter Viabahn Stent-Graft Placement for Femoropopliteal Diseases Requiring Endovascular Therapy (VANQUISH) Study. *Journal of Endovascular Therapy* 2021;28(1):123-131.

GORE, VIABAHN and designs are trademarks of W. L. Gore & Associates. © 2021 W. L. Gore & Associates, Inc.

VANQUISH Study: Study Endpoints[1]

- Primary endpoints
  - Primary patency at 12 months.
- Secondary endpoints
  - **Full coverage cohort:** Major amputation, surgical reconstruction, target lesion revascularization (TLR), acute thrombotic occlusion.
  - **Spot coverage cohort:** One-year primary patency.

1. Iida O, Takahara M, Soga Y, *et al*; VANQUISH Investigators. One-year outcomes of heparin-bonded stent-graft therapy for real-world femoropopliteal lesions and the association of patency with the prothrombotic state based on the prospective, observational, multicenter Viabahn Stent-Graft Placement for Femoropopliteal Diseases Requiring Endovascular Therapy (VANQUISH) Study. *Journal of Endovascular Therapy* 2021;28(1):123-131.

© 2021 W. L. Gore & Associates, Inc.

Overview of patient characteristics by study cohort[1]

Characteristic	Overall (n = 370)	Full lesion coverage (n = 301)	Spot coverage (n = 69)
Age, y	75 ± 8	75 ± 8	77 ± 8
Men	247 (66.8)	206 (68.4)	41 (59.4)
Smoking Status			
Never	102 (27.6)	82 (27.2)	20 (29.0)
Past	189 (51.1)	153 (50.8)	36 (52.2)
Current	79 (21.4)	66 (21.9)	13 (18.8)
Diabetes mellitus	212 (57.3)	166 (55.1)	46 (66.7)
Chronic renal failure without dialysis	67 (18.1)	56 (18.6)	11 (15.9)
Chronic renal failure with dialysis	66 (17.8)	51 (16.9)	15 (21.7)

© 2021 W. L. Gore & Associates, Inc.

1. Iida O, Takahara M, Soga Y, *et al*; VANQUISH Investigators. One-year outcomes of heparin-bonded stent-graft therapy for real-world femoropopliteal lesions and the association of patency with the prothrombotic state based on the prospective, observational, multicenter Viabahn Stent-Graft Placement for Femoropopliteal Diseases Requiring Endovascular Therapy (VANQUISH) Study. *Journal of Endovascular Therapy* 2021;28(1):123-131.

© 2021 W. L. Gore & Associates, Inc.

Overview of lesion characteristics by study cohort[1]

Characteristic	Overall (n = 423)	Full Lesion Coverage (n = 343)	Spot Coverage (n = 80)
Chronic limb-threatening ischemia	108 (25.5)	80 (23.3)	28 (35.0)
Ankle-brachial index	0.54 ± 0.21	0.55 ± 0.20	0.52 ± 0.22
Restenotic lesion	82 (19.4)	61 (17.8)	21 (26.2)
In-stent lesion	77 (18.2)	58 (16.9)	19 (23.8)
In-stent occlusion	51 (12.1)	36 (10.5)	15 (18.8)
Angiographic assessment			
TASC II class			
A	8 (1.9)	8 (2.3)	0 (0)
B	27 (6.4)	26 (7.6)	1 (1.2)
C	174 (41.1)	135 (39.4)	39 (48.8)
D	214 (50.6)	174 (50.7)	40 (50.0)
Lesion length, cm	26 ± 11	25 ± 12	30 ± 7
Chronic total occlusion	303 (71.6)	245 (71.4)	58 (72.5)
PACSS grade			
0	124 (29.3)	111 (32.4)	13 (16.2)
1	81 (19.1)	69 (20.1)	12 (15.0)
2	34 (8.0)	29 (8.5)	5 (6.2)
3	67 (15.8)	49 (14.3)	18 (22.5)
4	117 (27.7)	85 (24.8)	32 (40.0)

© 2021 W. L. Gore & Associates, Inc.

1. Iida O, Takahara M, Soga Y, *et al*; VANQUISH Investigators. One-year outcomes of heparin-bonded stent-graft therapy for real-world femoropopliteal lesions and the association of patency with the prothrombotic state based on the prospective, observational, multicenter Viabahn Stent-Graft Placement for Femoropopliteal Diseases Requiring Endovascular Therapy (VANQUISH) Study. *Journal of Endovascular Therapy* 2021;28(1):123-131.

© 2021 W. L. Gore & Associates, Inc.

Primary patency by treatment strategy[1]

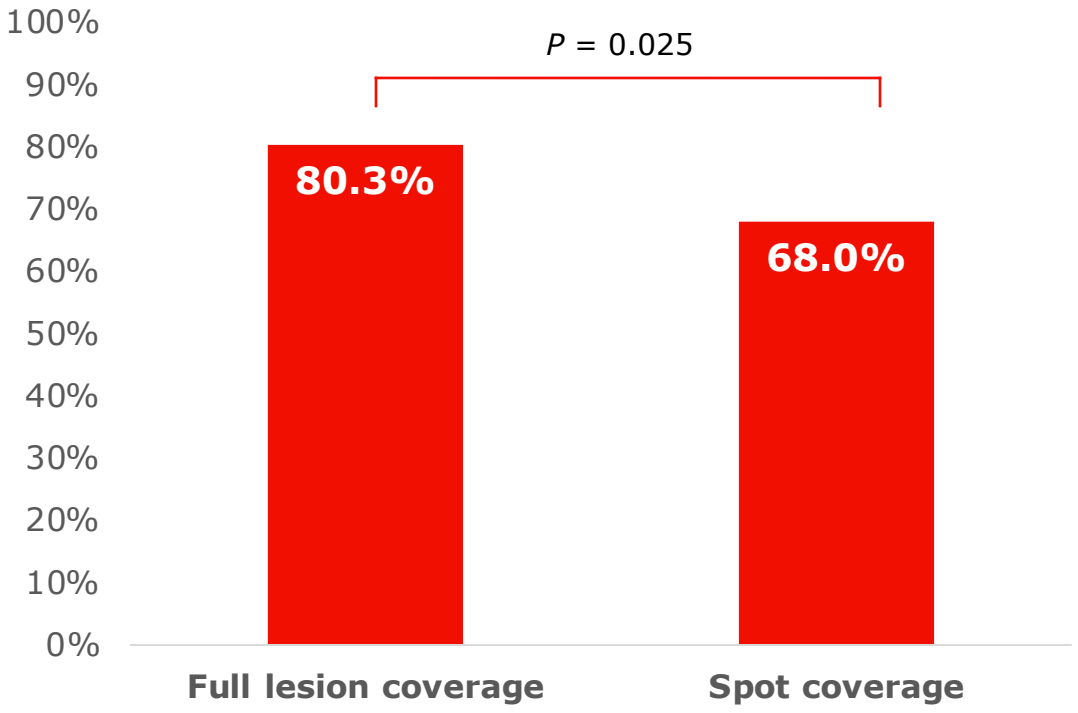

© 2021 W. L. Gore & Associates, Inc.

1. Iida O, Takahara M, Soga Y, *et al*; VANQUISH Investigators. One-year outcomes of heparin-bonded stent-graft therapy for real-world femoropopliteal lesions and the association of patency with the prothrombotic state based on the prospective, observational, multicenter Viabahn Stent-Graft Placement for Femoropopliteal Diseases Requiring Endovascular Therapy (VANQUISH) Study. *Journal of Endovascular Therapy* 2021;28(1):123-131.

© 2021 W. L. Gore & Associates, Inc.

Excellent patency and durability independent of lesion length[1–6,*]

- **Japan IDE Clinical Study:** 88.1% primary patency at one year in lesions 22 cm in length, with 79.1% fTLR through five years.[4]
- **Japan Post Market Clinical Study:** 85.6% primary patency at one year in lesions 24 cm in length with 26.5% critical limb ischemia (CLI).[6]
- **VANQUISH Study:** 80.3% 1-year primary patency with full lesion coverage in real-world complex disease with 90.1% of lesions classified as TASC II C & D (25 cm average lesion length).[7]

* Claim based on linear regression between average lesion length and one-year primary patency for the referenced studies.[1-6,8-12] $P = 0.8876$. P-value indicates t-test on slope of weighted-linear regression compared to zero. Prospective randomized or prospective multicenter superficial femoral artery studies using the GORE® VIABAHN® Endoprosthesis with Heparin Bioactive Surface. Patency definitions may vary; where Kaplan-Meier estimates with a PSVR > 2.5 are available, they are used for comparison.

1. Lammer J, Zeller T, Hausegger KA, *et al.* Sustained benefit at 2 years for covered stents versus bare-metal stents in long SFA lesions: the VIASTAR Trial. *Cardiovascular & Interventional Radiology* 2015;38(1):25-32.
2. Zeller T, Peeters P, Bosiers M, *et al.* Heparin-bonded stent-graft for the treatment of TASC II C and D femoropopliteal lesions: the Viabahn-25 cm Trial. *Journal of Endovascular Therapy* 2014;21(6):765-774.
3. Reijnen M, van Walraven L, Fritschy W, *et al.* 1-year results of a multicenter, randomized controlled trial comparing heparin-bonded endoluminal to femoropopliteal bypass. *Journal of Cardiovascular Interventions* 2017;10(22):2320-2331. https://www.sciencedirect.com/science/article/pii/S1936879817319775
4. Ohki T, Kichikawa K, Yokoi H, *et al.* Long-term results of the Japanese multicenter Viabahn trial of heparin bonded endovascular stent grafts for long and complex lesions in the superficial femoral artery. *Journal of Vascular Surgery.* In press.
5. Saxon RR, Chervu A, Jones PA, *et al.* Heparin-bonded, expanded polytetrafluoroethylene-lined stent graft in the treatment of femoropopliteal artery disease: 1-year results of the VIPER (Viabahn Endoprosthesis with Heparin Bioactive Surface in the Treatment of Superficial Femoral Artery Obstructive Disease) Trial. *Journal of Vascular & Interventional Radiology* 2013;24(2):165-173.
6. Iida 0. Twelve-month outcomes from the Japanese post-market surveillance study of the GORE® VIABAHN® Endoprosthesis as treatment for symptomatic peripheral arterial disease in the superficial femoral arteries. Presented at LEIPZIG Interventional Course (LINC)2021; January 25-29, 2021; Leipzig, Germany.
7. Iida O, Takahara M, Soga Y, *et al*; VANQUISH Investigators. One-year outcomes of heparin-bonded stent-graft therapy for real-world femoropopliteal lesions and the association of patency with the prothrombotic state based on the prospective, observational, multicenter Viabahn Stent-Graft Placement for Femoropopliteal Diseases Requiring Endovascular Therapy (VANQUISH) Study. *Journal of Endovascular Therapy* 2021;28(1):123-131.
8. Geraghty PJ, Mewissen MW, Jaff MR, Ansel GM; VIBRANT Investigators. Three-year results of the VIBRANT trial of VIABAHN endoprosthesis versus bare nitinol stent implantation for complex superficial femoral artery occlusive disease. *Journal of Vascular Surgery* 2013;58(2):386-395.e4
9. McQuade K, Gable D, Pearl G, Theune B, Black S. Four-year randomized prospective comparison of percutaneous ePTFE/ nitinol self-expanding stent graft versus prosthetic femoral-popliteal bypass in the treatment of superficial femoral artery occlusive disease. *Journal of Vascular Surgery* 2010;52(3):584-591.
10. Saxon RR, Coffman JM, Gooding JM, Ponec DJ. Long-term patency and clinical outcome of the Viabahn stent-graft for femoropopliteal artery obstructions. *Journal of Vascular & Interventional Radiology* 2007;18(11):1341-1350.
11. Lammer J, Zeller T, Hausegger KA, *et al*. Heparin-bonded covered stents versus bare-metal stents for complex femoropopliteal artery lesions: the randomized VIASTAR trial (Viabahn endoprosthesis with PROPATEN bioactive surface [VIA] versus bare nitinol stent in the treatment of long lesions in superficial femoral artery occlusive disease). *Journal of the American College of Cardiology* 2013;62(15):1320-1327.
12. Lammer J, Dake MD, Bleyn J, *et al.* Peripheral arterial obstruction: prospective study of treatment with a transluminally placed self-expanding stent graft. *Radiology* 2000;217(1):95-104.

GORE, VIABAHN and designs are trademarks of W. L. Gore & Associates. © 2021 W. L. Gore & Associates, Inc.

VIABAHN® Device recommendations

Device sizing considerations

- Treat all of the disease (stent "healthy-to-healthy").[1]
- Overlap devices by at least 1 cm.[1]
- Avoid excessive oversizing (> 20 percent).[1]

Procedural considerations

- Ensure adequate inflow and outflow.[1]
- Post dilate.[1]
- Do not use balloon angioplasty outside of the device.[1]
- Place device at the SFA origin if proximal SFA disease is present.[1]

Follow-up considerations

- Regular duplex ultrasonography. follow-up.[2]
- Prescribe appropriate antiplatelet therapy.[1]
- Treat progressing disease.[2]

1. GORE® VIABAHN® Endoprosthesis with Heparin Bioactive Surface *Instructions for Use* (IFU). W. L. Gore & Associates, Inc website. Accessed July 28, 2020. https://eifu.goremedical.com/
2. Troutman DA, Madden NJ, Dougherty MJ, Calligaro KD. Duplex ultrasound diagnosis of failing stent grafts placed for occlusive disease. *Journal of Vascular Surgery* 2014;60(6):1580-1584.

GORE, VIABAHN and designs are trademarks of W. L. Gore & Associates. © 2021 W. L. Gore & Associates, Inc.

Case Studies

The outcomes and observations reported are based on individual case experience and the patients treated. The steps described here may not be complete, and are not intended to be a replacement for the *Instructions for Use* or the education, training and professional judgment of healthcare providers (HCP). HCPs remain solely responsible for making decisions about patient care and the use of medical technologies.

© 2021 W. L. Gore & Associates, Inc.

Case: Endovascular treatment of chronic SFA occlusion for limb salvage

- Patient
  - 83-year-old with ischemic gangrene of her right great toe (Rutherford 6).
  - Diabetes, hypertension, hyperlipidemia, obesity, coronary artery disease, atrial fibrillation, chronic kidney disease, COPD.
  - Ankle brachial index (ABI) supra-systemic due to calcified tibial arteries.
  - Pulse volume recordings demonstrated femoropopliteal occlusive disease.

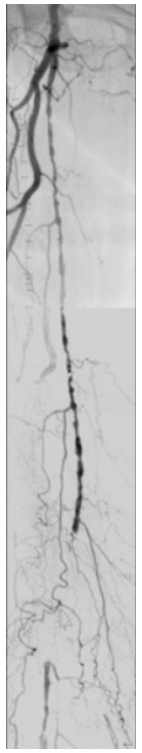

Proximal SFA disease and mid-SFA occlusion

What are your considerations for treating?

Case and images courtesy of James Persky, M.D. Used with permission.

© 2021 W. L. Gore & Associates, Inc.

Case: Endovascular treatment of chronic SFA occlusion for limb salvage

- Procedure
  - Contralateral approach to right SFA (March 05, 2013).
  - Lesion crossed using straight TERUMO GLIDEWIRE® Guidewire, followed by placement of SPECTRANETICS® QUICK-CROSS Support Catheter.
  - Percutaneous transluminal angioplasty (PTA) with 5 mm angioplasty balloon.

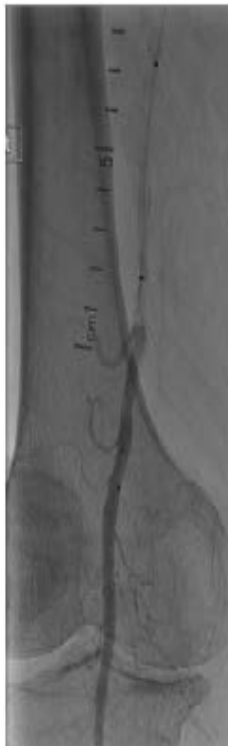

Lesion crossed

Case and images courtesy of James Persky, M.D. Used with permission.

SPECTRANETICS and QUICK-CROSS are trademarks of Spectranetics Corporation. TERUMO and GLIDEWIRE are trademarks of Terumo Medical Corporation.
© 2021 W. L. Gore & Associates, Inc.

Case: Endovascular treatment of chronic SFA occlusion for limb salvage

- Results
  - Proximal device placed successfully at the ostium of the SFA.
  - Correct sizing with 5 mm VIABAHN® Device.
  - Excellent radiographic result.
  - Patient's ulcer healed after intervention.
  - Stent grafts patent through most recent follow-up approximately 15 months after procedure.

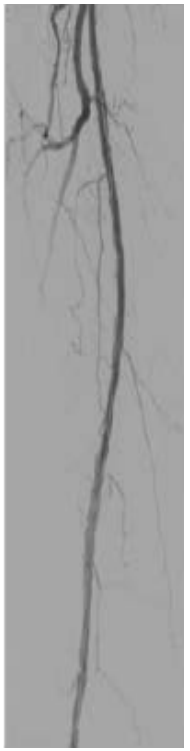

Result after PTA

Post-placement of three 5 mm VIABAHN® Devices

Case and images courtesy of James Persky, M.D. Used with permission.

GORE, VIABAHN and designs are trademarks of W. L. Gore & Associates. © 2021 W. L. Gore & Associates, Inc.

Case: Endovascular treatment of chronic SFA occlusion for limb salvage

- Case takeaways
  - Limb salvage by endoluminal bypass in Rutherford 6 limb.
  - While initial PTA demonstrated a good result, diabetic patients have diffuse disease and the arteriogram may understate the plaque burden in these patients.
  - Cover healthy-to-healthy to the extent possible.

© 2021 W. L. Gore & Associates, Inc.

Case: Non-healing ulcer with SFA disease

- Patient
  - 72-year-old male with non-healing left foot ulceration (Rutherford 5) and leg edema.
  - Diabetes with peripheral neuropathy and congestive heart failure.
  - Prior interventions.
    - February 2009: Left femoral to below-knee bypass with right saphenous vein (claudication).
    - September 2010: Vein bypass thrombosed, with unsuccessful attempt to treat the graft at outside institution; developed non-healing ulcer on top of left foot; calcified ABIs, with toe pressure of 20 mmHg on left and 34 mmHg on right. No palpable pulses below left femoral level.
    - October 2011: Left SFA treatment.

Left SFA CTO with one-vessel runoff (not shown)

Case and images courtesy of Bruce Gray, M.D. Used with permission.

© 2021 W. L. Gore & Associates, Inc.

Case: Non-healing ulcer with SFA disease

- Procedure
  - Subintimal traversal without re-entry, followed by PTA and then re-entry using a CORDIS® OUTBACK® Device.
  - Deployed two 6 mm x 15 cm VIABAHN® Devices.

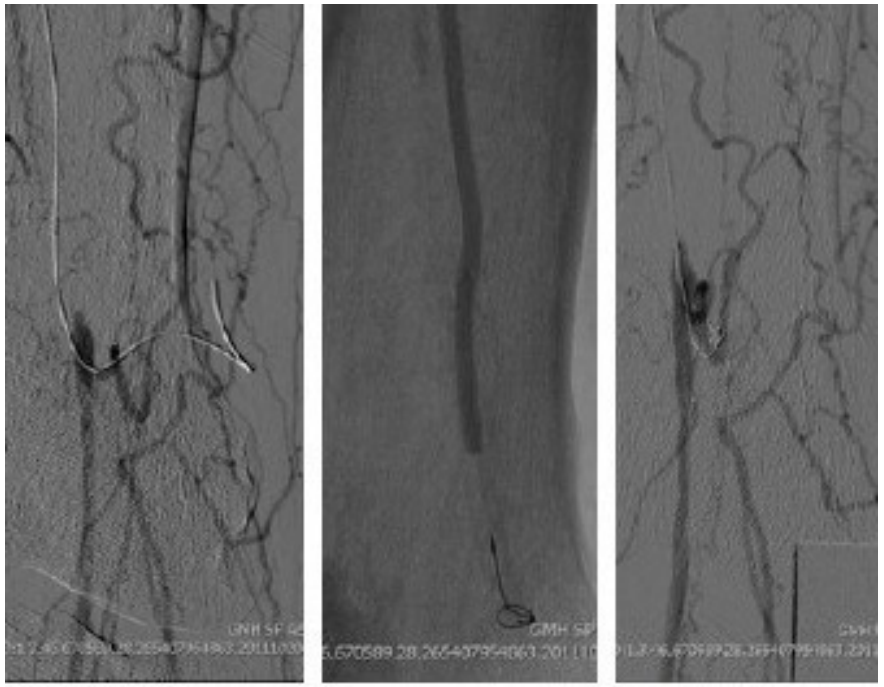

Case and images courtesy of Bruce Gray, M.D. Used with permission.

CORDIS and OUTBACK are trademarks of Cordis Corporation.
GORE, VIABAHN and designs are trademarks of W. L. Gore & Associates. © 2021 W. L. Gore & Associates, Inc.

Case: Non-healing ulcer with SFA disease

- Results
  - Maintained one-vessel runoff.
  - The patient went home after three hours with palpable dorsalis pedis pulse, ABI of 1.0.
  - Long-term anticoagulation/antiplatelet regimen: COUMADIN® (warfarin sodium) and ASPIRIN (acetylsalicylic acid) Surveillance with duplex ultrasound within one month then at six months.
  - No recurrence of ulceration or need for other interventions and no amputations.
  - The patient died 11 months later (in September 2012) of respiratory failure associated with his congestive heart failure.

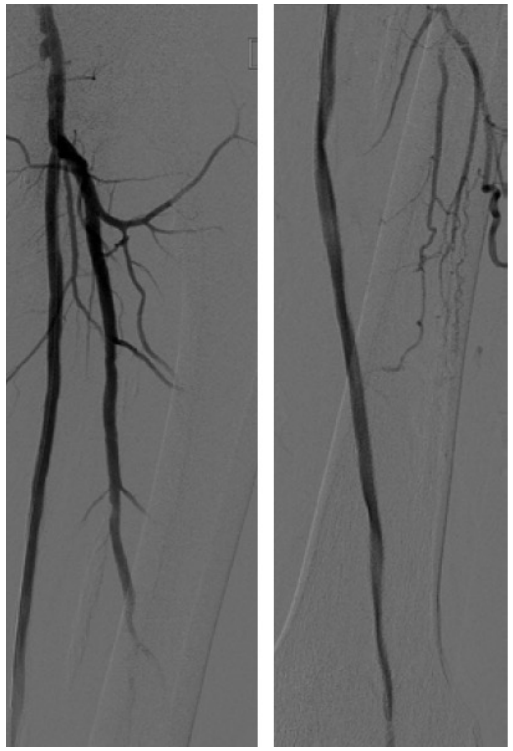

Post-placement of two 6 mm x 15 cm VIABAHN® Devices. Maintained one-vessel runoff (not shown).

Case and images courtesy of Bruce Gray, M.D. Used with permission.

GORE, VIABAHN and designs are trademarks of W. L. Gore & Associates. © 2021 W. L. Gore & Associates, Inc.

Case: Non-healing ulcer with SFA disease

- Case takeaways
  - Successful recanalization of SFA CTO in critical limb ischemia (CLI) patient.
  - Good inline flow through the SFA with preservation of tibial runoff.
  - Healing of ulcer and limb preservation in CLI patient.
  - Consider duplex ultrasound at frequent intervals through the first year, especially when runoff is limited.

© 2021 W. L. Gore & Associates, Inc.

Q & A

© 2021 W. L. Gore & Associates, Inc.

Thank you

© 2021 W. L. Gore & Associates, Inc.

Consult Instructions for Use
eifu.goremedical.com

INTENDED USE/INDICATIONS: The GORE® VIABAHN® Endoprosthesis with Heparin Bioactive Surface is indicated for improving blood flow in patients with symptomatic peripheral arterial disease in superficial femoral artery de novo and restenotic lesions up to 270 mm in length with reference vessel diameters ranging from 4.0 – 7.5 mm. The GORE® VIABAHN® Endoprosthesis with Heparin Bioactive Surface is indicated for improving blood flow in patients with symptomatic peripheral arterial disease in superficial femoral artery in-stent restenotic lesions up to 270 mm in length with reference vessel diameters ranging from 4.0 – 6.5 mm. The GORE® VIABAHN® Endoprosthesis with Heparin Bioactive Surface is indicated for improving blood flow in patients with symptomatic peripheral arterial disease in iliac artery lesions up to 80 mm in length with reference vessel diameters ranging from 4.0 – 12 mm. The GORE® VIABAHN® Endoprosthesis with Heparin Bioactive Surface is also indicated for the treatment of stenosis or thrombotic occlusion at the venous anastomosis of synthetic arteriovenous (AV) access grafts. **CONTRAINDICATIONS:** The GORE® VIABAHN® Endoprosthesis with Heparin Bioactive Surface is contraindicated for non-compliant lesions where full expansion of an angioplasty balloon catheter was not achieved during pre-dilatation, or where lesions cannot be dilated sufficiently to allow passage of the delivery system. Do not use the GORE® VIABAHN® Endoprosthesis with Heparin Bioactive Surface in patients with known hypersensitivity to heparin, including those patients who have had a previous incident of Heparin-Induced Thrombocytopenia (HIT) type II. Refer to *Instructions for Use* at eifu.goremedical.com for a complete description of all applicable indications, warnings, precautions and contraindications for the markets where this product is available. ℞ Only

Products listed may not be available in all markets.

CORDIS and OUTBACK are trademarks of Cordis Corporation. MEDTRONIC and IN.PACT are trademarks of Medtronic, Inc. SPECTRANETICS and QUICK-CROSS are trademarks of Spectranetics Corporation. TERUMO and GLIDEWIRE are trademarks of Terumo Medical Corporation.
CBAS is a trademark of Carmeda AB, a wholly owned subsidiary of W. L. Gore & Associates, Inc.
GORE, HEMOBAHN, VIABAHN and designs are trademarks of W. L. Gore & Associates.
© 2021 W. L. Gore & Associates, Inc. 21309303-EN NOVEMBER 2021

W. L. Gore & Associates, Inc.
Flagstaff, AZ 86004

+65 67332882 (Asia Pacific)
1800 680 424 (Australia / New Zealand)
00800 6334 4673 (Europe)
800 437 8181 (United States)
928 779 2771 (United States)

goremedical.com